

· 专题报道 ·

ZNF262 在常染色体显性多囊肾病患者肾组织中的表达及意义

王素霞,王 丽,刘亚伟,付莉莉,许 涛,梅长林*

(第二军医大学长征医院肾内科,解放军肾脏病研究所,上海 200003)

[摘要] **目的:**检测锌指蛋白 262(ZNF262)在正常肾组织及不同发病阶段多囊肾组织中的表达,并以增殖细胞核抗原(PCNA)为对照,初步探讨 ZNF262 在常染色体显性多囊肾病(autosomal dominant polycystic kidney disease, ADPKD)中的作用。**方法:**根据肾小球滤过率(GFR)大小对 ADPKD($n=8$)进行分期,观察其影像学、常规病理检查结果,采用半定量 RT-PCR 方法检测人正常肾组织($n=8$)、早期多囊肾组织($n=4$)、晚期多囊肾组织($n=4$)中 ZNF262 和 PCNA 的表达,并对上述组织中 ZNF262 和 PCNA 的表达进行相关性分析。**结果:**与正常肾组织相比,ZNF262 和 PCNA 在早期、晚期多囊肾组织中的表达均显著增多($P<0.01$),且晚期多囊肾组织表达高于早期多囊肾组织($P<0.05$)。ZNF262 和 PCNA 在早期、晚期多囊肾及正常肾组织中的表达存在显著的相关性($r_1=0.8426$, $r_2=0.9021$, $r_3=0.8835$,均 $P<0.05$)。**结论:**与正常组织相比,ZNF262 不仅在 ADPKD 高表达,并且随着病程进展表达逐步增高,这与 PCNA 的表达具有显著的相关性。提示 ZNF262 可以作为检测 ADPKD 的指标,并有助于临床进展分期的判别。

[关键词] 锌指蛋白 262;增殖细胞核抗原;多囊肾,常染色体显性

[中图分类号] R 692.12 **[文献标识码]** A **[文章编号]** 0258-879X(2006)06-0581-04

Expression of zinc finger protein 262 mRNA in patients with autosomal-dominant polycystic kidney disease and its significance

WANG Su-xia, WANG Li, LIU Ya-wei, FU Li-li, XU Tao, MEI Chang-lin* (Department of Nephrology, Changzheng Hospital, Second Military Medical University, Kidney Disease Research Institute of PLA, Shanghai 200003, China)

[ABSTRACT] **Objective:** To investigate the expression of zinc finger protein 262 (ZNF262) mRNA in normal kidney tissues and kidney tissues of patients with autosomal-dominant polycystic kidney disease (ADPKD) at different stages, and to explore the role of ZNF262 in pathogenesis of ADPKD. **Methods:** Patients with ADPKD were staged according to glomerular filter rate (GFR). Imaging observation and routine pathological examination were performed. The expression of ZNF262 mRNA and proliferating cell nuclear antigen (PCNA) mRNA in normal kidney tissues ($n=8$), early stage ADPKD kidney tissues ($n=4$) and advanced stage ADPKD kidney tissues ($n=4$) was examined by semi-quantitative RT-PCR. The correlation between the expressions of the 2 genes was investigated in all tissue specimens. **Results:** Expression of ZNF262 mRNA and PCNA mRNA in early and advanced ADPKD kidney tissues was significantly higher than that in normal renal tissues (both $P<0.01$), and that in the advanced stage ADPKD was significantly higher than that in early stage ADPKD (both $P<0.05$). The expression of ZNF262 and PCNA mRNA was highly correlated in the early, advanced ADPKD and normal renal tissues ($r_1=0.8426$, $r_2=0.9021$ and $r_3=0.8835$, respectively, all $P<0.05$). **Conclusion:** The ZNF262 mRNA level is higher in ADPKD kidney tissue than that in normal control and increases with the advancement of ADPKD. The expression of ZNF262 is significantly correlated with the expression of PCNA in the same renal tissues. The expression of ZNF262 mRNA may serve as an indicator in diagnosis of ADPKD and may be used for clinical staging of ADPKD patients.

[KEY WORDS] zinc finger protein 262; proliferating cell nuclear antigen; polycystic kidney, autosomal dominant

[Acad J Sec Mil Med Univ, 2006, 27(6): 581-584]

常染色体显性多囊肾病(autosomal dominant polycystic kidney disease, ADPKD)是人类最常见的单基因遗传性疾病,其基本的发病机制为囊肿衬里上皮细胞异常增殖,合成细胞外基质(extracellular matrix, ECM)增多和分泌囊液增多。锌指蛋白 ZNF262,其蛋白产物主要通过 DNA 相互作用而起转录因子作用,调节靶基因的表达以适应生物体发育、分化、成熟过程的需要^[1]。本研究所早期研究

[基金项目] 国家自然科学基金重点项目(30330640);国家自然科学基金面上项目(30271523);国家自然科学基金(30576867)。Supported by Key Program of National Natural Science Foundation of China(30330640), General Program of National Natural Science Foundation of China(30271523) and National Natural Science Foundation of China(30576867)。

[作者简介] 王素霞,硕士生。E-mail:huhusuxia@yahoo.com.cn

* Corresponding author. E-mail:chlmei1954@126.com

发现 ZNF262 在多囊肾组织中表达谱上调^[2]。据此,我们从核酸水平观察了 ZNF262 在正常肾组织和不同发病阶段的多囊肾组织中的表达,以初步探讨其在 ADPKD 发病中的作用。

1 材料和方法

1.1 材料、试剂及仪器 8例正常肾组织标本来自本院泌尿外科肾癌切除的正常组织,8例 ADPKD 肾组织标本取自本院泌尿外科行单侧肾脏切除术或囊肿去顶减压术的患者。固定标本常规石蜡包埋并切片。部分新鲜肾组织短暂冻存用于抽提组织 RNA。

RNA 抽提试剂盒(上海华舜生物工程有限公司),逆转录试剂盒(日本 TaKaRa),PCR 引物用 Primer Premier 5.0 设计并由博亚生物有限公司合成,参照人 ZNF262 GenBank 上的序列(gi: 44890067)。P1: 5'-GTG ATG AGA CGG ACC AGG AC-3' (4 624 bp), P2: 5'-CAG GGT CTA TCG GGA ATG TG-3' (4 299 bp), 目的片段长 326 bp。人 PCNA (gi: 189681)。P1 5'-TGC ATG AGA TGG GAG AAT GA-3' (4 445 bp), P2: 5'-AGC AAG CCC TGT CTC AAA AA-3' (4 906 bp), 目的片段长 472 bp。内参 β -actin (gi: 5016088), P1: 5'-GAA AAT CTG GCA CCA CAC CT-3' (322 bp), P2 5'-AGG AAG GAA GGC TGG AAG AG-3' (873 bp), 目的片段长 552 bp。超滤离心机(美国 Millipore), PCR 仪(美国 Bio-RADiCycler), TaKaRa Del2000 marker, 显微镜(日本 Olympus), 病理切片机(德国 LEICA), IDA-2000 病理图文分析系统, HDI-5000 超声诊断仪。

1.2 肾功能检查 测定患者血肌酐、尿素及血白蛋白。根据 MDRD 公式^[3]计算肾小球滤过率(GFR): $GFR(\text{ml}/\text{min}) = 170 \times \text{血肌酐}(\text{mg}/\text{dl})^{-0.999} \times (\text{年龄}/0.357)^{0.176} \times \text{血尿素}(\text{mg}/\text{dl})^{-0.170} \times \text{血白蛋白}(\text{g}/\text{dl})^{-0.318} \times 0.762$ (女性)。按美国肾脏病学会的慢性肾脏病操作指南标准^[4]分为 2 组, 4 例为早期(GFR > 90 ml/min), 4 例为晚期(GFR < 15 ml/min)。

1.3 超声检查 探头频率 3.5 MHz, 观察患者双肾大小^[3]、囊肿数量及大小、肾血流情况。

1.4 常规病理 H-E 染色 切片常规脱蜡至水, 苏木精染色 3 min, 1% 盐酸分化数秒, 流水冲洗返蓝, 伊红染色 30 s, 脱水, 透明, 封固。光学显微镜下观察, 摄片。

1.5 RT-PCR 按说明书分别抽取总 RNA, 取 5 μ l

总 RNA 进行 1% 甲醛变性凝胶电泳, 电泳结果可见 28S、18S、5S 3 条清晰完整的带, 证实所提取的总 RNA 完整可靠。将总 RNA 用适量 dH₂O 稀释后于紫外分光光度计扫描测定, 其 D_{260}/D_{280} 稳定在 1.8~2.0 之间, 表明所提取之总 RNA 质量较好, 同时读取其浓度并使各检测标本的细胞 RNA 浓度调至一致。两步法 RT-PCR 试剂盒购自 Promega 公司, 反应体系按说明书, 第一步: 逆转录反应, 条件为 42°C 30 min, 99°C 5 min, 5°C 5 min。第二步: PCR 反应, 条件为 94°C 灭活 5 min, 然后扩增 ZNF262 (94°C, 30 s; 61°C, 30 s; 72°C, 30 s), PCNA (94°C, 5 min; 94°C, 30 s; 60°C, 35 s; 72°C 40 s), 各 30 个循环, 最后 72°C 延伸 10 min。内对照与各基因扩增条件相同。各组织细胞 RT-PCR 实验重复 6 次。PCR 产物电泳后凝胶成像, 以 pImage 软件分析, 结果以目的基因与 β -actin 的灰度之比表示表达强度。

1.6 统计学处理 采用方差分析(ANOVA)及相关性分析。

2 结果

2.1 两组 ADPKD 患者肾脏体积、囊肿数量及大小与肾功能变化的情况 在两组 ADPKD 患者中, 晚期患者肾脏体积显著增大, 囊泡数量明显增多、增大, 肾血流量显著减少; 而正常肾脏未见任何囊泡状结构, 肾体积及肾血流量未见明显异常(图 1)。

2.2 常规病理结果 光镜下观察可见早期部分肾小管形态正常, 小管上皮细胞明显水肿, 部分小管空泡变性, 皮质、髓质部分小管管径增大, 形成大小不等的囊肿, 囊肿形态不规则, 囊肿衬里细胞增殖显著(图 2B)。晚期绝大部分小管高度扩张, 成为大小不等、形态不规则的囊肿, 囊肿衬里细胞明显增殖(图 2C), 正常肾组织小球、小管排列规整, 结构未见明显异常(图 2A)。

2.3 RT-PCR 见图 3。正常肾组织、早期多囊肾组织、晚期多囊肾组织中 ZNF262 的表达强度依次为 0.58 ± 0.03 、 1.09 ± 0.05 、 1.19 ± 0.05 , 而 PCNA 的表达强度依次为 0.83 ± 0.03 、 0.90 ± 0.05 、 0.96 ± 0.04 。统计学分析表明, 与正常组织相比, 早期多囊肾、晚期多囊肾组织中 ZNF262 表达明显增多, 差异有显著的统计学意义($P < 0.01$), 早期、晚期多囊肾组织间表达量的差异有显著的统计学意义($P < 0.05$); PCNA 在早、晚期多囊肾组织中的表达均显著高于正常肾组织($P < 0.01$), 早、晚期多囊肾组织间表达量的差异也有显著的统计学意义($P < 0.05$)。ZNF262 和 PCNA 在早、晚期多囊肾及正常

肾组织中的表达存在显著相关性($r_1=0.8426, r_2=0.9021, r_3=0.8835$, 均 $P<0.05$)。

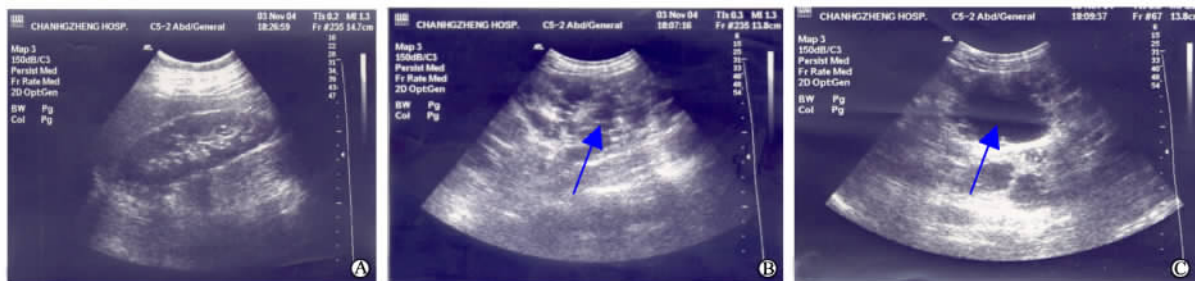

图 1 不同肾脏组织超声检查图像

Fig 1 Ultrasound results of different renal tissues

A: Normal renal tissue; B: Renal tissues at early stage of ADPKD; C: Renal tissues at advanced stage of ADPKD. Arrows showing the cysts

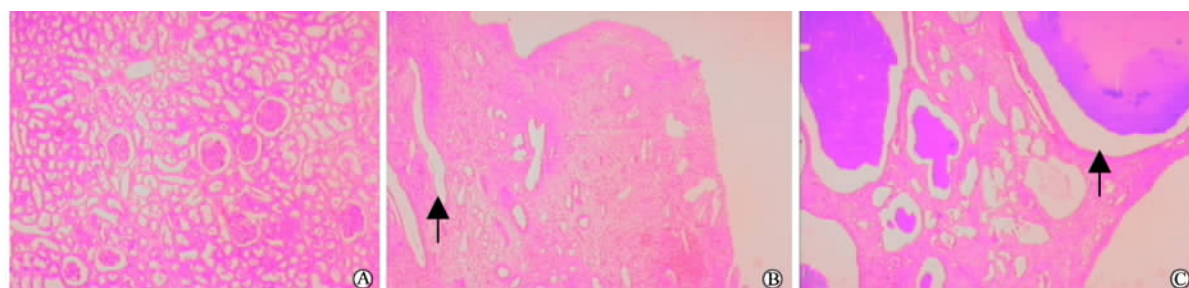


图 2 肾脏组织 H-E 染色结果

Fig 2 H-E staining of different renal tissues($\times 100$)

A: Normal renal tissue; B: Renal tissues at early stage of ADPKD; C: Renal tissues at advanced stage of ADPKD. Arrows showing the cysts




图 3 肾脏组织 ZNF262 和 PCNA RT-PCR 结果

Fig 3 RT-PCR results of ZNF262 and PCNA in different renal tissues

M: Del2000 marker; 1: Normal renal tissue; 2: Renal tissues at early stage of ADPKD; 3: Renal tissues at advanced stage of ADPKD

3 讨论

ZNF262 位于人染色体 1p34-p32, 又称细胞死亡抑制 RNA (cell death inhibiting RNA), 是锌指结

合区 (MYM) 家族成员之一。据欧洲分子生物学实验室 (EMBL) 相关数据库 Harvester 介绍, 它在胚胎干细胞、胚胎组织、Ewing 肉瘤中表达较高。最近的研究表明其在肺鳞癌和腺癌中也有一定量表达^[5], 可能与其抑制细胞死亡有关。ZNF262 在胚胎发育中具有一定的刺激细胞增殖作用, 在胚胎干细胞和发育中的神经组织有显著表达^[6]。有研究^[7]表明 ADPKD 衬里上皮细胞存在着过度增殖或凋亡, 但 ZNF262 与 ADPKD 的关系尚未见报道。

本研究结果表明, ZNF262 和 PCNA 在 ADPKD 患者肾组织中的表达显著高于正常人, 而对于患者本身, ZNF262 和 PCNA 在晚期多囊肾组织的表达水平又明显高于早期多囊肾组织。PCNA 为一种在增殖期细胞中表达的多肽, 细胞增殖越活跃, PCNA 表达水平越高。因此, PCNA 表达水平可反映细胞的增殖能力。相对于正常肾小管上皮细胞, 多囊肾衬里上皮细胞具有增殖迅速、极性逐渐消失及至呈囊性变等特点。从本研究发现的 ZNF262 和 PCNA 在上述组织基因表达较为一致性和相关性较强来看, 推测 ZNF262 可能通过其抑制凋亡、促进增殖的作用参与了 ADPKD 的发生和发展。

本研究还根据影像学、病理及 GFR 结果, 发现

随着肾脏体积的增大、小管囊肿的增大增多、肾功能的恶化,ADPKD患者肾组织中的ZNF262水平逐渐升高。但是ZNF262与不同阶段ADPKD的发生发展到底有多密切的相关性,还需要大样本资料的统计和更深入的研究来证实。

与正常组织相比,ZNF262不仅在ADPKD高表达,而且随着病程进展表达逐步增高,并与PCNA的表达具有显著的相关性。提示ZNF262不仅与细胞增殖有关,而且可能在ADPKD中存在较特异的高表达现象。

[参考文献]

[1] Brown RS. Zinc finger proteins: getting a grip on RNA[J]. *Curr Opin Struct Biol*,2005,15:94-98.
 [2] 梅长林,张维莉,葛守一,等. 利用基因表达图谱芯片研究多囊肾组织基因表达变化[J]. *肾脏病与透析肾移植杂志*,2002,11:307-322.

[3] Fick-Brosnahan GM, Belz MM, McFann KK, et al. Relationship between renal volume growth and renal function in autosomal dominant polycystic kidney disease: a longitudinal study [J]. *Am J Kidney Dis*, 2002,39:1127-1134.
 [4] Levey AS, Coresh J, Balk E, et al. National Kidney Foundation practice guidelines for chronic kidney disease: evaluation, classification, and stratification[J]. *Ann Intern Med*,2003,139:137-147.
 [5] McDoniels-Silvers AL, Nimri CF, Stoner GD, et al. Differential gene expression in human lung adenocarcinomas and squamous cell carcinomas[J]. *Clin Cancer Res*,2002,8:1127-1138.
 [6] Sohal J, Chase A, Goldman JM, et al. Assignment of ZNF262 to human chromosome band 1p34→p32 by *in situ* hybridization [J]. *Cytogenet Cell Genet*,1999,85(3-4):306-307.
 [7] Nadasdy T, Laszik Z, Lajoie G, et al. Proliferative activity of cyst epithelium in human renal cystic disease[J]. *J Am Soc Nephrol*,1995,5:1462-1468.

[收稿日期] 2006-01-04 [修回日期] 2006-03-20
 [本文编辑] 李丹阳

Expression of p28GANK and its correlation with RB in human hepatocellular carcinoma

Tan L, Fu XY, Liu SQ, Li HH, Hong Y, Wu MC, Wang HY (International Cooperation Laboratory on Signal Transduction, Eastern Hepatobiliary Surgery Institute, Second Military Medical University, Shanghai 200438, China)

[ABSTRACT] **Background:** Aberrance of retinoblastoma protein (RB) signal pathway is known to play an important role in the carcinogenesis of human hepatocellular carcinoma (HCC). p28GANK, originally purified from human 26S proteasome as a non-ATPase subunit, was recently found in HCC and shown to interact with RB. The aim of this study was to investigate the expression profile of p28GANK and its correlation with RB in HCC. **Methods:** The expression of p28GANK was evaluated in 55 surgically resected HCCs by immunohistochemistry (IHC), and the associations were explored between p28GANK level and clinicopathologic features as well as tumor suppressor RB. Western blotting was performed to determine p28GANK expression level in 12 HCCs. Immunofluorescence stainings of p28GANK and RB in U2-OS cells were examined by confocal microscopy. **Results:** Positive p28GANK cytoplasmic staining was recognized in 55 HCCs. Nuclear positive occurrence of p28(GANK) in HCCs was more frequent than paracancerous hepatic tissues ($P < 0.05$). The overexpression probability of p28GANK was inversely associated with Edmonson's grade; overexpression occurred in nine out of 11 (81.8%), 22 out of 35 (62.9%) and two out of nine (22.2%) in I-III and IV graded cases, respectively ($P = 0.004$). Total cellular expression of p28GANK had curvilinear correlation with the nuclear expression of RB ($r = 0.475$, $P = 0.019$), while the nuclear expression of p28GANK had not. Western blot analysis showed that up-regulation of p28GANK expression was found in nine out of 12 HCCs compared with paracancerous liver tissues. Exogenously expressed p28GANK colocalized with RB in cytoplasm of U2-OS cells. **Conclusion:** These results confirm the role of p28GANK as a highly expressed oncoprotein in HCC by *in situ* examination. Its overexpression correlates with the differentiation status of HCC. The whole cellular p28GANK activation, not nuclear portion only, influences the alteration of RB. Underlying nuclear translocation of p28GANK may contribute to the counteraction against RB through a feed back loop. These data provide new evidence for p28GANK to be used as a promising drug target of a therapeutic agent against HCC.

[Liver Int,2005,25:667-676]