

DOI:10.16781/j.0258-879x.2021.02.0133

· 专题报道 ·

创伤性颈内动脉颅内段假性动脉瘤的血管内治疗

赵 瑞[△], 路智文[△], 邓晓东, 邹 超, 左 乔, 赵开军, 戴冬伟, 方亦斌, 李 强, 黄清海, 洪 波, 许 奕, 刘建民*
海军军医大学(第二军医大学)长海医院脑血管病中心, 上海 200433

[摘要] **目的** 回顾性分析单中心血管内治疗创伤性颈内动脉颅内段假性动脉瘤(TIICAP)的安全性及临床疗效。**方法** 连续回顾2005年9月至2019年9月我中心收治的经脑血管造影检查的颅内动脉瘤患者资料,根据纳入标准选择TIICAP患者。分析患者的手术策略及围手术期抗血小板药物治疗情况,并总结治疗效果和临床与影像学随访结果。**结果** 共入组29例TIICAP患者,男19例(65.5%),女10例(34.5%),年龄为14~70岁,中位年龄为47(30,53)岁。29例患者均成功实施血管内治疗,其中采用覆膜支架3例,血流导向装置9例,支架辅助弹簧圈栓塞11例,单纯弹簧圈栓塞2例,载瘤动脉闭塞4例。1例行载瘤动脉闭塞患者术前再出血,术后死亡;1例行载瘤动脉闭塞患者术后发生缺血性脑卒中,最终死亡;余27例患者均无并发症发生,顺利出院。23例患者接受影像学随访,13例治愈,5例好转,2例稳定,3例复发(均再次行血管内治疗治愈)。24例患者接受临床随访,临床预后均稳定或好转。**结论** 血管内治疗是处理TIICAP的有效手段,其中血流导向装置、覆膜支架等新技术的优势初现,值得进一步研究。

[关键词] 颈内动脉;创伤性假性动脉瘤;血管内治疗;血流导向装置;弹簧圈栓塞;支架

[中图分类号] R 654.34 **[文献标志码]** A **[文章编号]** 0258-879X(2021)02-0133-07

Endovascular treatment of traumatic intracranial internal carotid artery pseudoaneurysm

ZHAO Rui[△], LU Zhi-wen[△], DENG Xiao-dong, ZOU Chao, ZUO Qiao, ZHAO Kai-jun, DAI Dong-wei, FANG Yi-bin, LI Qiang, HUANG Qing-hai, HONG Bo, XU Yi, LIU Jian-min*

Stroke Center, Changhai Hospital, Naval Medical University (Second Military Medical University), Shanghai 200433, China

[Abstract] **Objective** To retrospectively analyze the safety and clinical efficacy of endovascular treatment for traumatic intracranial internal carotid artery pseudoaneurysm (TIICAP) in a single center. **Methods** The data of patients with intracranial aneurysms, who underwent cerebral angiography from Sep. 2005 to Sep. 2019 in our Stroke Center, were reviewed consecutively. Patients with TIICAP were selected according to the inclusion criteria. The operative methods and perioperative antiplatelet drug treatment strategies were analyzed, and the therapeutic effect and clinical and imaging follow-up results were summarized. **Results** A total of 29 patients with TIICAP were enrolled, including 19 (65.5%) males and 10 (34.5%) females, with a median age of 47 (30, 53) years (range, 14-70 years). Endovascular treatment was successfully performed in the 29 cases, including 3 cases treated with covered stent implantation, 9 with flow diverter implantation, 11 with stent-assisted coiling embolization, 2 with coiling embolization and 4 with parent artery occlusion. One patient receiving parent artery occlusion suffered from rebleeding before operation, and died after operation. One patient receiving parent artery occlusion had ischemic stroke and died after operation. None of the remaining 27 patients had complications. Twenty-three patients were followed up by imaging. Thirteen of them were cured, 5 were improved, 2 were stable and 3 had recurrence, and the 3 recurrence cases were cured by endovascular treatment again. Twenty-four patients had clinical follow-up data, and the clinical outcomes were stable or improved. **Conclusion** Endovascular treatment is an effective method for TIICAP. The preliminary superiorities of novel techniques, including flow diverter and covered stent, deserve further confirmation.

[Key words] internal carotid artery; traumatic pseudoaneurysm; endovascular treatment; flow diverter; coil embolization; stent

[Acad J Sec Mil Med Univ, 2021, 42(2): 133-139]

[收稿日期] 2020-09-06 **[接受日期]** 2020-12-18

[基金项目] 国家重点研发计划(2016YFC1300700),国家自然科学基金(81671137,81571126,8187093),2016年中国脑卒中高危人群干预适宜技术研究及推广项目(GN-2016R0012)。Supported by National Key Research and Development Plan of China (2016YFC1300700), National Natural Science Foundation of China (81671137, 81571126, 8187093), and 2016 Project of Research and Application of Effective Intervention Techniques for High-risk Stroke Population of China (GN-2016R0012).

[作者简介] 赵 瑞,博士,副教授、副主任医师。E-mail: z_ray1979@126.com;路智文,博士生,住院医师。E-mail: lzwlz828@163.com

[△]共同第一作者(Co-first authors).

*通信作者(Corresponding author). Tel: 021-31161784, E-mail: chstroke@163.com

创伤性颈内动脉颅内段假性动脉瘤 (traumatic intracranial internal carotid artery pseudoaneurysm, TIICAP) 是因动脉壁直接损伤导致,常继发于钝性或穿透性颅脑创伤,亦可由经鼻蝶入路垂体瘤手术等医源性损伤造成^[1]。TIICAP 缺乏完整的血管壁结构,极易发生破裂出血造成严重后果且好发于走行在前颅底骨质结构内的颈内动脉段,外科手术操作困难。近年来, TIICAP 血管内治疗逐渐开展,但其安全性和疗效的相关报道较少。本研究回顾性收集 2005 年 9 月至 2019 年 9 月我院脑血管病中心收治的 TIICAP 患者资料,探讨血管内治疗的安全性和临床疗效。

1 资料和方法

1.1 研究对象 回顾性选择 2005 年 9 月至 2019 年 9 月我院脑血管病中心收治的所有行脑血管造影检查的颅内动脉瘤患者。纳入标准: (1) 确诊 TIICAP; (2) 行血管内介入治疗; (3) 影像学资料完整。

1.2 治疗与随访

1.2.1 手术方法 对于拟行血管重建的患者采用覆膜支架或血流导向装置植入;对于拟行动脉瘤栓塞治疗的患者采用支架辅助弹簧圈栓塞、重叠支架辅助弹簧圈或单纯弹簧圈栓塞;而对拟行载瘤动脉闭塞的患者,经球囊闭塞试验 (balloon occlusion test, BOT) 评估后,采用弹簧圈或弹簧圈+Onyx 胶栓塞。除拟行载瘤动脉闭塞前的局部麻醉下 BOT 评估外,其他手术均在全身麻醉下进行。经右侧股动脉,采用 Seldinger 法穿刺置鞘,全身肝素化,脑血管造影明确动脉瘤位置后选择合适的工作角度,采用导引导管建立通路。弹簧圈栓塞: 6 F 导引导管沿导丝经右侧股动脉送至患侧颈内动脉。微导管在微导丝引导下超选至瘤体内,根据造影结果选择合适大小的弹簧圈经微导管进行栓塞,至造影见瘤腔栓塞满意时结束。普通支架、覆膜支架及血流导向装置释放: 选择合适大小的支架或血流导向装置,经患侧颈内动脉内的微导管释放,确保支架覆盖瘤颈并完全打开、贴壁良好。可根据需要在支架内重叠释放另一枚支架。载瘤动脉闭塞: 首先予股动脉穿刺置鞘, 8 F 导引导管送至患侧颈内动

脉,采用合适尺寸的球囊于动脉瘤颈处充盈闭塞患侧颈内动脉 40 min,检查患者神经功能无缺损,泄球囊撤出。改全身麻醉,经微导管向患侧颈内动脉填入 1.5 倍血管直径规格的弹簧圈,完全闭塞动脉瘤颈的远近端,直至同侧颈内动脉和对侧颈内动脉造影见动脉瘤均不显影,必要时联合 Onyx 胶注射完全闭塞载瘤动脉。

1.2.2 围手术期用药 术后抗血小板药物使用方面,载瘤动脉闭塞和瘤腔单纯弹簧圈栓塞的患者无须抗血小板治疗。覆膜支架和血流导向装置植入患者,术前 3~5 d 开始口服硫酸氢氯吡格雷片 75 mg/d,至术后 3 个月停药;口服阿司匹林肠溶片 300 mg/d 至术后 6 周,之后改为 100 mg/d 终身服用。采用支架辅助弹簧圈栓塞患者,术前 3~5 d 开始口服硫酸氢氯吡格雷片 75 mg/d,至术后 6 周停药;口服阿司匹林肠溶片 100 mg/d 至术后 6 个月以上,建议终身服用。

1.2.3 随访 所有患者术后均采取临床和影像学随访。临床随访时间为术后 3 个月、6 个月及 1 年,之后每年进行临床随访。根据格拉斯哥结局量表 (Glasgow outcome scale, GOS) 评分判断患者的预后情况: GOS 评分 4~5 分为预后良好, GOS 评分 1~3 分为预后不良,记录出院时及末次随访时的 GOS 评分。影像学随访为术后 3 个月复查头颅磁共振血管造影 (magnetic resonance angiography, MRA), 术后半年复查数字减影血管造影 (digital subtraction angiography, DSA), 并根据此次 DSA 检查结果判断动脉瘤治愈、好转、稳定及复发。好转及稳定患者继续观察,术后 1 年再次复查 DSA; 复发患者建议再次治疗。

1.3 统计学处理 应用 SPSS 20.0 软件进行数据处理。计量资料首先采用 Shapiro-Wilk 方法进行正态性检验,若服从正态分布以 $\bar{x} \pm s$ 表示,不服从正态分布以中位数 (下四分位数,上四分位数) 表示。计数资料以例数 (次) 和百分数表示。

2 结果

2.1 患者基本资料 共入组 29 例 TIICAP 患者,患者资料见表 1。

表 1 29 例创伤性颈内动脉颅内段假性动脉瘤患者临床资料

Tab 1 Clinical data of 29 patients with traumatic intracranial internal carotid artery pseudoaneurysm

No.	Gender	Age/ year	Lesion location	D_{\max} / mm	Treatment strategy	Embolitic material	Surgical outcome		Follow-up outcome ^a	
							DSA	GOS score	DSA	GOS score
1	Male	16	Paraclinoid	11	Balloon-assisted coiling	Onyx + coils	Residual neck	5	Cured	5
2	Male	47	Cavernous	4.4	Covered stent implantation	Coils	Complete occlusion	5	—	—
3	Female	45	Supraclinoid	11.6	Parent artery occlusion	Onyx + coils	Complete occlusion	1	—	—
4	Female	48	Petrous	18	FD implantation	Coils	Residual aneurysm	5	Cured	5
5	Male	44	Paraclinoid	16.7	Parent artery occlusion after BOT	Coils	Complete occlusion	4	—	—
6	Male	53	Cavernous	9	Overlapping stents with coils	Coils	Residual aneurysm	5	Improved, cured in second follow-up	5
7	Male	33	Supraclinoid	5	Covered stent implantation	Not used	Complete occlusion	5	Cured	5
8	Male	54	Petrous	19	Stent-assisted coiling	Coils	Residual aneurysm	5	Improved, cured in second follow-up	5
9	Female	70	Cavernous	7	Stent-assisted coiling	Coils	Complete occlusion	5	Cured	5
10	Female	53	Paraclinoid	28	Overlapping stents with coils	Coils	Residual aneurysm	5	Improved, cured in second follow-up	5
11	Male	66	Petrous	19	FD implantation	Not used	Residual aneurysm	5	Stable, cured in second follow-up	5
12	Female	53	Lacerum	17	FD implantation	Coils	Residual aneurysm	5	—	—
13	Male	47	Paraclinoid	5	Stent-assisted coiling	Coils	Residual aneurysm	5	Recurrence, cured after second treatment	5
14	Male	51	Cavernous	7.7	Stent-assisted coiling	Coils	Residual aneurysm	5	Cured	5
15	Male	49	Cavernous	16	Stent-assisted coiling	Coils	Residual neck	4	Improved, cured in second follow-up	5
16	Male	50	Lacerum	11	Overlapping stents with coils	Coils	Residual neck	5	Cured	5
17	Female	32	Lacerum	7.8	FD implantation	Not used	Residual aneurysm	4	Improved, cured in second follow-up	5
18	Male	53	Cavernous	10	FD implantation	Not used	Residual aneurysm	5	Cured	5
19	Female	53	Lacerum	5.6	Coil embolization	Coils	Complete occlusion	5	Cured	5
20	Female	14	Supraclinoid	4	Parent artery occlusion after BOT	Coils	Complete occlusion	5	Cured	5
21	Male	18	Supraclinoid	4.6	FD implantation	Coils	Complete occlusion	3	—	3
22	Female	49	Paraclinoid	12	FD implantation	Coils	Residual aneurysm	5	Cured	5
23	Male	17	Paraclinoid	3.2	Overlapping stents with coils	Coils	Complete occlusion	5	Cured	5
24	Male	38	Cavernous	15	FD implantation	Coils	Residual neck	5	Stable, cured in second follow-up	5
25	Female	67	Supraclinoid	12	Parent artery occlusion after BOT	Onyx + coils	Complete occlusion	1	—	—
26	Male	34	Cavernous	18	Stent-assisted coiling	Coils	Complete occlusion	5	Recurrence, cured after second treatment	5
27	Male	23	Cavernous	11	Covered stent implantation	Not used	Complete occlusion	5	Cured	5
28	Male	28	Cavernous	19	Stent-assisted coiling	Coils	Complete occlusion	5	Recurrence, cured after third treatment	5
29	Male	16	Supraclinoid	8	FD implantation	Coils	Complete occlusion	5	Cured	5

^a: Six months after endovascular treatment. —: No follow-up data. D_{\max} : Maximum diameter; DSA: Digital subtraction angiography; GOS: Glasgow outcome scale; FD: Flow diverter; BOT: Balloon occlusion test.

29例患者中男19例(65.5%),女10例(34.5%);年龄为14~70岁,中位年龄为47(30,53)岁。合并外伤22例(75.9%),其中2例为经鼻蝶入路垂体瘤切除术中损伤颈内动脉,5例同时合并创伤性颈动脉海绵窦瘘(tramatic carotid-cavernous fistula, TCCF)。受伤至发病时间为1~365 d,中位时间为60(14,90) d。11例患者临床表现为鼻出血,1例脑脊液鼻漏,6例头痛,2例头晕,5例患者有眼部症状(视物模糊、视物重影、眼球胀痛),7例无症状。头颅CT检查示8例患者合并颅骨骨折,其中6例有不同程度的颅底骨折;9例合并颅内出血,其中4例有蛛网膜下腔出血,5例脑出血,1例硬脑膜下出血,1例硬脑膜外出血。入院时格拉斯哥昏迷量表(Glasgow coma scale, GCS)评分 ≤ 8 分者1例,9~12分2例,13~14分1例,15分25例。

2.2 DSA检查结果 动脉瘤位于岩段3例,破裂孔段4例,海绵窦段10例,床突上段6例,床突旁6例。动脉瘤最大径为3.2~28 mm,平均(11.6 \pm 6.1) mm。4例行载瘤动脉闭塞患者术后即刻造影动脉瘤均不显影;25例非载瘤动脉闭塞患者中,10例动脉瘤完全不显影,4例颈颈残留,11例瘤体残留,其中瘤体内造影剂明显淤滞3例,25例患者载瘤动脉均通畅。见表1。

2.3 治疗情况与临床结果 29例患者均顺利行血管内治疗,围手术期均按前述抗血小板方案规律用药。采用覆膜支架治疗3例(2例Willis覆膜支架,1例Jostent覆膜支架);血流导向装置治疗9例(1例采用Pipeline支架,8例采用Tubridge支架);支架辅助弹簧圈栓塞11例(BX球囊扩张支架1例次,Enterprise支架2例次,LEO支架4例次,LVIS支架4例次,Solitaire支架1例次),其中4例采用重叠支架技术;单纯弹簧圈栓塞2例;载瘤动脉闭塞4例,其中3例先行BOT均呈阴性。除3例单纯血流导向装置植入患者及2例单纯覆膜支架植入患者外,其余24例患者均合并弹簧圈栓塞。见表1。

行血管重建和单纯弹簧圈栓塞的25例患者均无手术并发症发生,出院时GOS评分为5分者22例、4分2例(术前GCS评分分别为12和15分)、3分1例(术前GCS评分为10分)。4例行载瘤动脉

闭塞的患者中2例自动出院后死亡,其中1例入院时GCS评分为7分,术前出现双侧瞳孔散大,头颅CT检查提示再出血、脑积水,术中BOT阴性,载瘤动脉闭塞后复查CT见出血未增加,进一步行双侧脑室外引流术,术后仍深度昏迷,双侧瞳孔未恢复,无自主呼吸,后自动出院;另1例为在外院行经鼻蝶入路垂体瘤切除术患者,因术中颈内动脉损伤导致右侧鼻腔大出血转至我院,入院GCS评分为15分,急诊予颈内动脉闭塞治疗,未行BOT,术后发生缺血性脑卒中,因中枢性尿崩和水、电解质及酸碱平衡紊乱导致病情进行性恶化,自动出院后死亡。余2例行载瘤动脉闭塞患者在出院时1例GOS评分为5分,1例4分。总体手术并发症发生率为3.4%(1/29),死亡率为6.9%(2/29)。见表1。

2.4 随访结果 29例患者除2例自动出院后死亡、3例失访外,共24例接受临床随访,其中1例患者因明显残疾(GOS评分为3分)拒绝影像学随访,23例患者完成MRA和DSA随访。随访期间患者均遵医嘱服用抗血小板药物,未出现与抗血小板药物相关的出血或缺血并发症。

23例患者影像学随访1~108个月,中位随访时间为18(9,53)个月。第1次(术后6个月)DSA复查时13例患者治愈,5例好转,2例稳定,3例(13.0%)复发。3例复发患者首次治疗时均采用支架辅助弹簧圈栓塞,复发后均再次行血管内治疗。其中1例患者术后4年复查DSA提示复发,二次治疗采用血流导向装置+弹簧圈栓塞,7个月后复查DSA显示治愈(图1);1例患者术后6个月复查DSA提示复发,予单纯弹簧圈栓塞2年后复查MRA显示治愈;第3例患者术后6个月复查DSA提示复发,再先后经过2次单纯弹簧圈栓塞治疗,7个月后复查DSA显示治愈。余7例好转和稳定患者术后第2次DSA复查均提示治愈。

24例患者临床随访1~168个月,中位随访时间为40(15,102)个月。其中23例患者GOS评分为5分,其中2例患者GOS由4分转为5分(术前GCS评分分别为12和15分);1例仍为3分(术前GCS评分为10分)。临床预后良好率为95.8%(23/24)。见表1。

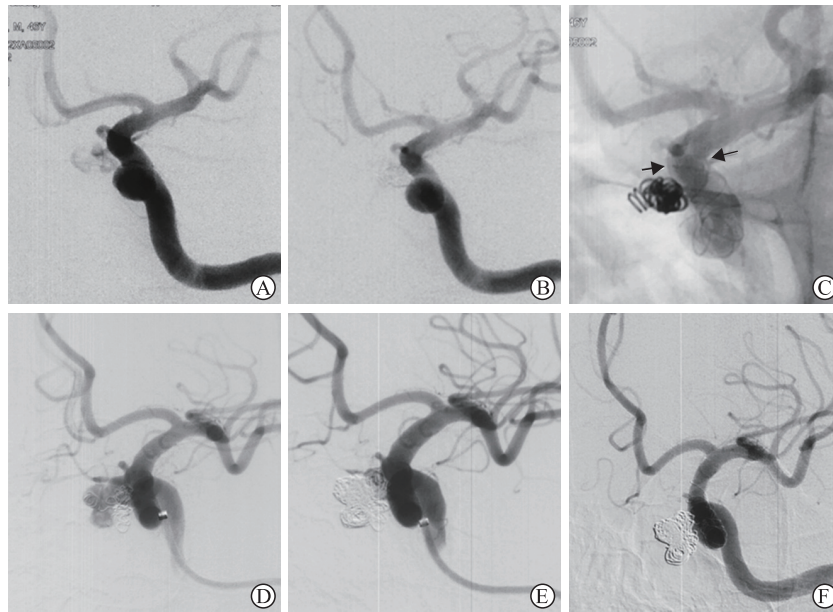


图 1 1例颈内动脉床突旁创伤性假性动脉瘤术后复发二次治疗患者的影像学表现

Fig 1 Imaging findings in a patient with recurrent traumatic pseudoaneurysm of internal carotid artery paraclinoid segment undergoing second treatment

Male, 47 years old. A: Angiography showed a pseudoaneurysm in paraclinoid segment of internal carotid artery before treatment; B, C: Angiography with (B) or without (C) subtraction showed LVIS stent and coils (arrows) immediately after stent-assisted embolization; D: The aneurysm recurred and the coils were displaced 4 years after the first treatment; E: The second treatment was performed with Tubridge device and coils; F: Seven months after the second treatment, angiography showed the aneurysm was cured.

3 讨论

创伤性血管损伤是颅脑创伤的严重并发症，尽管发生率不高（0.80%~1.67%），但其自然病程预后差^[2]，脑卒中发生率高达25%~50%，残死率高，在战创伤中越来越受到重视^[3]。创伤性假性动脉瘤（traumatic pseudoaneurysm, TPA）是创伤性血管损伤的常见类型。TIICAP的致伤因素较多，其中以头面部钝性外伤导致颅底骨折直接损伤动脉最常见^[4]，TIICAP极易破裂，破裂后可导致鼻衄（海绵窦段动脉瘤）和颅内出血（眼动脉段以远动脉瘤）等严重后果^[5-7]，残死率高^[8]。因此，早期有效治疗对于TIICAP患者预后尤为重要。

目前有关TIICAP治疗的报道并不多。早期治疗以外科手术为主，包括颈动脉结扎（单独或结合颅内外血管搭桥）、假性动脉瘤切除和颈内动脉破口修补手术等，但因颅底手术难度大、创伤严重、术后效果欠理想，目前已经较少采用。血管内治疗是近年来更普遍的治疗方法，包括可脱球囊或弹簧圈栓塞动脉瘤及颈内动脉^[6]、Onyx胶栓塞^[9]、覆膜支架植入^[10]、支架辅助弹簧圈栓塞^[11]、血流导向装置植入^[12]等技术。治疗策略也从最初的

牺牲载瘤动脉逐渐转为载瘤动脉重建。本组29例患者中，除4例行载瘤动脉闭塞、2例单纯弹簧圈栓塞外，23例采用了保留载瘤动脉的血管重建治疗，治疗策略的转变离不开介入材料和技术进步的支撑。

本研究中仅1例（3.4%）行载瘤动脉闭塞的TIICAP患者术后发生缺血性并发症，提示血管内治疗具有较高的安全性，与文献^[13]报道一致。血管内治疗对于预防TPA破裂出血的效果亦值得肯定。Zhang等^[14]对6例颈内动脉假性动脉瘤患者行血管内治疗，仅1例单纯弹簧圈栓塞患者术后2个月动脉瘤复发破裂出血，通过再次栓塞治愈。本组29例患者围手术期均未发生动脉瘤（再）出血，24例接受临床随访的患者亦未见动脉瘤破裂出血，提示血管内治疗对TPA有效。此外，支架血管重建术后抗血小板治疗对损伤组织出血的影响不容忽视，本研究中23例支架治疗患者在随访期间均未发生因使用抗血小板药物导致的出血问题，这可能与本研究纳入的大部分患者治疗时已度过创伤急性期有关。

由于假性动脉瘤的瘤壁由水肿和周围组织构成，血管内治疗后瘤壁水肿的吸收消散可能导致动脉瘤复发和再出血。故早期血管内治疗都是在

BOT 阴性后采用载瘤动脉闭塞术或动脉瘤孤立术^[13,15]。Chen 等^[13]通过对 20 例 TPA 患者行颈内动脉球囊闭塞治疗认为该治疗方式安全性高,临床疗效好。但也存在一些问题,诸如颈内动脉闭塞无法适用于 BOT 阳性患者,并且即使 BOT 阴性,也有一定比例的患者在载瘤动脉闭塞后发生迟发性脑缺血^[16];此外,颈内动脉闭塞导致的脑血流动力学变化可能增加前交通动脉瘤的发生风险,单侧颈内动脉闭塞患者若合并动脉粥样硬化性狭窄时其发生缺血性脑卒中的风险可能增加。由于假性动脉瘤的瘤壁并无血管壁成分,在真性动脉瘤治疗中常用的单纯弹簧圈栓塞瘤腔方法并不适合假性动脉瘤,该治疗方式复发率高,尽管早期有对颈内动脉瘤行单纯弹簧圈栓塞治疗的报道^[6,16],但临床很少应用。笔者认为该治疗方式可用于不适合行抗血小板治疗的动脉瘤破裂出血急性期患者的暂时过渡性治疗,待度过急性期再行支架、覆膜支架或血流导向装置等血管重建性治疗,本组有 1 例患者采用该策略治疗成功。

支架辅助弹簧圈栓塞治疗宽颈假性动脉瘤是一种较好的血管重建方法。本研究中支架辅助弹簧圈栓塞治疗策略包括单一支架和重叠支架,动脉瘤总体复发率为 13.0% (3/23), 3 例复发均为单一支架辅助弹簧圈栓塞患者,而 4 例采用重叠支架辅助弹簧圈栓塞患者均未复发。重叠支架技术最早见于 2001 年^[17],后续的临床应用也证实其在夹层、假性动脉瘤中的疗效优于单一支架技术^[11]。而对于假性动脉瘤的治疗经验多来源于颈内动脉血泡样动脉瘤。笔者所在中心牵头的多中心回顾性病例研究显示,重叠支架治疗血泡样动脉瘤的随访闭塞率 (78.4%~88.2%) 远高于单一支架治疗组 (42.9%),同时动脉瘤复发率显著下降^[18]。单中心研究还显示,重叠的编织支架 LVIS 较非编织支架对假性动脉瘤有更高的治愈率^[19]。综合本研究结果及文献报道,对 THCAP 患者的支架血管重建治疗,重叠支架的治愈率较单一支架更高。

目前认为重叠支架的高治愈率主要与其金属覆盖率增高带来的血流动力学改变有关,而血流导向装置正是这一技术理念的产物。近年来研究显示,采用血流导向装置治疗血泡样动脉瘤的治愈率较传统支架更高^[20]。笔者所在中心通过 meta 分析回顾性分析了 165 枚血流导向装置治疗的血泡样动脉瘤,其完全闭塞率为 72%,复发率为 13%,

手术相关并发症发生率为 26%,死亡率为 3%,优于传统支架^[21]。但关于采用血流导向装置治疗假性动脉瘤的报道较少,且多为小样本研究和个案报道^[12,20]。本研究中所有血流导向装置治疗病例均未见复发,并且能够促进传统支架术后复发病例的治愈,初步证明了血流导向装置在 TPA 治疗方面的优越性。

尽管血流导向装置改变了动脉瘤局部的血流动力学,但并没有将瘤腔彻底隔绝,在血流冲击下依然存在复发和再出血风险。而覆膜支架则能彻底隔绝瘤腔,从而即刻止血,并真正达到解剖修复破损动脉管壁的目的^[22],对于无重要分支节段的 THCAP,覆膜支架具有较好的疗效。Chen 等^[13]报道的 11 例行 Willis 覆膜支架治疗的 TPA 患者均无手术并发症,随访 11 个月亦均无复发和破裂出血。Tsai 等^[23]报道了 7 例采用覆膜支架治疗的 TPA 患者,除 1 例死于术后感染性休克外,6 例随访见动脉瘤均愈合且无支架内狭窄发生。本研究中 3 例患者采用覆膜支架治疗,其中 2 例随访结果显示动脉瘤均愈合。然而,覆膜支架表面的聚四氟乙烯膜也存在一定缺陷,支架释放不理想可能出现内漏,术后还需要更强效、更长久的抗血小板药物治疗;此外,由于聚四氟乙烯膜可诱使血管内膜增生,与裸支架相比术后发生支架内再狭窄的风险较高,随访时需关注管腔的充盈缺损^[24]。总之,对于血管条件允许的 TPA 患者,覆膜支架植入是一种可以即刻隔离血流、彻底止血的安全和有效的治疗手段,但需注意其与裸支架的差异。

本研究也存在局限性。本研究回顾了单中心 14 年的病例,受限于 THCAP 发病率较低,样本例数仍显不足,难以对各种治疗方法的安全性和有效性进行亚组分析,今后将继续扩充样本量,逐步解决这一局限。

综上所述,血管内治疗 THCAP 安全性较高,长期疗效确切。初步结果显示,血流导向装置或覆膜支架治疗具有更高的安全性和有效性,但还需要更多样本和更长时间的随访进一步验证。

[参 考 文 献]

- [1] 周景义,虞军,陈盛,吴群,许璟,张建民. 颈内动脉-椎动脉起源性假性动脉瘤及其处理[J]. 中华医学杂志, 2010,90:2338-2341.
- [2] ORLOWSKI H LP, KANSAGRA A P, SIPE A L, MILLER-THOMAS M M, VO K D, GOYAL M S.

- Utility of CT angiography in screening for traumatic cerebrovascular injury[J]. *Clin Neurol Neurosurg*, 2018, 172: 27-30.
- [3] BROMMELAND T, HELSETH E, AARHUS M, MOEN K G, DYRSKOG S, BERGHOLT B, et al. Best practice guidelines for blunt cerebrovascular injury (BCVI) [J/OL]. *Scand J Trauma Resusc Emerg Med*, 2018, 26: 90. DOI: 10.1186/s13049-018-0559-1.
- [4] PELLICCIA P, BARTOLOMEO M, IANNETTI G, BONAFÉ A, MAKEIEFF M. Traumatic intra-sphenoidal pseudoaneurysm lodged inside the fractured sphenoidal sinus[J]. *Acta Otorhinolaryngol Ital*, 2016, 36: 149-152.
- [5] RUIZ-JURETSCHKE F, CASTRO E, MATEO SIERRA O, IZA B, MANUEL GARBIZU J, FORTEA F, et al. Massive epistaxis resulting from an intracavernous internal carotid artery traumatic pseudoaneurysm: complete resolution with overlapping uncovered stents[J]. *Acta Neurochir (Wien)*, 2009, 151: 1681-1684.
- [6] AL-JEHANI H M, ALWADAANI H A, ALMOLANI F M. Traumatic intracranial internal carotid artery pseudoaneurysm presenting as epistaxis treated by endovascular coiling[J]. *Neurosciences (Riyadh)*, 2016, 21: 60-63.
- [7] MENON G, HEGDE A, NAIR R. Post-traumatic cavernous carotid pseudoaneurysm with delayed epistaxis[J/OL]. *Cureus*, 2018, 10: e3002. DOI: 10.7759/cureus.3002.
- [8] ERIC NYAM T T, HO C H, CHIO C C, LIM S W, WANG J J, CHANG C H, et al. Traumatic brain injury increases the risk of major adverse cardiovascular and cerebrovascular events: a 13-year, population-based study[J/OL]. *World Neurosurg*, 2019, 122: e740-e753. DOI: 10.1016/j.wneu.2018.10.130.
- [9] MEDEL R, CROWLEY R W, HAMILTON D K, DUMONT A S. Endovascular obliteration of an intracranial pseudoaneurysm: the utility of Onyx[J]. *J Neurosurg Pediatr*, 2009, 4: 445-448.
- [10] ALEXANDER M J, SMITH T P, TUCCI D L. Treatment of an iatrogenic petrous carotid artery pseudoaneurysm with a Symbiot covered stent: technical case report[J]. *Neurosurgery*, 2002, 50: 658-662.
- [11] LIM Y C, KANG J K, CHUNG J. Reconstructive stent-buttressed coil embolization of a traumatic pseudoaneurysm of the supraclinoid internal carotid artery[J]. *Acta Neurochir (Wien)*, 2012, 154: 477-480.
- [12] AMENTA P S, STARKE R M, JABBOUR P M, TJOUMAKARIS S I, GONZALEZ L F, ROSENWASSER R H, et al. Successful treatment of a traumatic carotid pseudoaneurysm with the Pipeline stent: case report and review of the literature[J/OL]. *Surg Neurol Int*, 2012, 3: 160. DOI: 10.4103/2152-7806.105099.
- [13] CHEN G, LI J, XU G, QIN S, GONG J, YANG M, et al. Diagnosis and treatment of traumatic internal carotid artery pseudoaneurysm primarily manifested by repeated epistaxis[J]. *Turk Neurosurg*, 2013, 23: 716-720.
- [14] ZHANG C W, XIE X D, YOU C, MAO B Y, WANG C H, HE M, et al. Endovascular treatment of traumatic pseudoaneurysm presenting as intractable epistaxis[J]. *Korean J Radiol*, 2010, 11: 603-611.
- [15] CHEN D, CONCUS A P, HALBACH V V, CHEUNG S W. Epistaxis originating from traumatic pseudoaneurysm of the internal carotid artery: diagnosis and endovascular therapy[J]. *Laryngoscope*, 1998, 108: 326-331.
- [16] ZHENG Y, LU Z, SHEN J, XU F. Intracranial pseudoaneurysms: evaluation and management[J/OL]. *Front Neurol*, 2020, 11: 582. DOI: 10.3389/fneur.2020.00582.
- [17] BENNDORF G, HERBON U, SOLLMANN W P, CAMPI A. Treatment of a ruptured dissecting vertebral artery aneurysm with double stent placement: case report[J]. *AJNR Am J Neuroradiol*, 2001, 22: 1844-1848.
- [18] FANG Y, ZHU D, PENG Y, ZHONG M, XU J, LI Q, et al. Treatment of blood blister-like aneurysms with stent-assisted coiling: a retrospective multicenter study[J/OL]. *World Neurosurg*, 2019, 126: e486-e491. DOI: 10.1016/j.wneu.2019.02.076.
- [19] ZHU D, FANG Y, YANG P, ZHANG P, CHEN L, XU Y, et al. Overlapped stenting combined with coiling for blood blister-like aneurysms: comparison of low-profile visualized intraluminal support (LVIS) stent and non-LVIS stent[J]. *World Neurosurg*, 2017, 104: 729-735.
- [20] NERVA J D, MORTON R P, LEVITT M R, OSBUN J W, FERREIRA M J, GHODKE B V, et al. Pipeline embolization device as primary treatment for blister aneurysms and iatrogenic pseudoaneurysms of the internal carotid artery[J]. *J Neurointerv Surg*, 2015, 7: 210-216.
- [21] ZHU D, YAN Y, ZHAO P, DUAN G, ZHAO R, LIU J, et al. Safety and efficacy of flow diverter treatment for blood blister-like aneurysm: a systematic review and meta-analysis[J/OL]. *World Neurosurg*, 2018, 118: e79-e86. DOI: 10.1016/j.wneu.2018.06.123.
- [22] LIU Y, YANG H F, XIONG Z Y, ZHENG J, LIU C Y, ZHAO H Y, et al. Efficacy and safety of Willis covered stent for treatment of complex vascular diseases of the internal carotid artery[J]. *Ann Vasc Surg*, 2019, 61: 203-211.
- [23] TSAI Y H, WONG H F, WENG H H, CHEN Y L. Stent-graft treatment of traumatic carotid artery dissecting pseudoaneurysm[J]. *Neuroradiology*, 2010, 52: 1011-1016.
- [24] LIU L X, SONG M Y, XIE X D. In-stent stenosis in the patient with internal carotid aneurysm after treated by the Willis covered stent: two case reports and literature review[J/OL]. *Medicine (Baltimore)*, 2017, 96: e6101. DOI: 10.1097/MD.00000000000006101.