

DOI:10.16781/j.CN31-2187/R.20230123

· 论 著 ·

头颈动脉夹层药物治疗前后的高分辨率磁共振成像特征分析

李 帅[△], 李 澌[△], 张雪凤*, 彭雯佳, 田 冰, 田 霞, 陈录广, 侯雨希, 刘 崎, 陆建平, 邵成伟
海军军医大学(第二军医大学)第一附属医院放射诊断科, 上海 200433

[摘要] **目的** 分析自发性未破裂头颈动脉夹层(CCAD)患者药物治疗前后高分辨率磁共振成像(HR-MRI)特征变化。**方法** 回顾性连续收集2015年8月至2022年12月于海军军医大学(第二军医大学)第一附属医院确诊并在药物治疗前后行HR-MRI检查的30例CCAD患者资料。根据随访时磁共振血管成像(MRA)图像上夹层血管管腔狭窄的改善情况,将患者分为改善组(随访时管腔狭窄程度较基线减轻1个级别及以上的患者)与未改善组(随访时管腔狭窄程度较基线加重1个级别及以上或无变化的患者)。分析改善组与未改善组患者的临床资料及治疗前后HR-MRI管腔及管壁特征差异。**结果** 30例CCAD患者共计30处夹层,其中改善组14例(11例完全恢复正常,3例管腔狭窄程度改善)、未改善组16例。改善组患者的年龄小于未改善组[(37.86±9.83)岁 vs (56.94±9.86)岁, $P=0.001$],其余临床特征差异均无统计学意义($P>0.05$)。改善组患者中基线壁内血肿比例高、管腔狭窄程度相对较轻,而未改善组患者的基线管腔狭窄程度较重,内膜瓣与双腔征、假腔内血栓形成更常见($P<0.05$)。治疗后随访时,改善组患者壁内血肿、管腔狭窄程度均改善,未改善组患者壁内血肿、内膜瓣与双腔征、假腔内血栓形成仍有较多残留($P<0.05$)。两组基线夹层血管壁强化程度差异无统计学意义($P>0.05$),治疗后随访时改善组患者血管壁强化程度较未改善组降低($P<0.001$)。**结论** HR-MRI可对CCAD药物治疗前后管腔及管壁形态学特征变化进行评估,年龄小、基线管腔狭窄程度相对较轻的患者经药物治疗后夹层恢复好。

[关键词] 头颈动脉夹层; 高分辨率磁共振成像; 抗凝剂; 抗血小板药; 预后; 青年卒中

[中图分类号] R 543.4; R 743.3

[文献标志码] A

[文章编号] 2097-1338(2023)06-0679-07

High-resolution magnetic resonance imaging characteristics of cervicocranial arterial dissection before and after drug treatment

LI Shuai[△], LI Si-chun[△], ZHANG Xue-feng*, PENG Wen-jia, TIAN Bing, TIAN Xia, CHEN Lu-guang, HOU Yu-xi, LIU Qi, LU Jian-ping, SHAO Cheng-wei

Department of Radiology, The First Affiliated Hospital of Naval Medical University (Second Military Medical University), Shanghai 200433, China

[Abstract] **Objective** To analyze the changes of high-resolution magnetic resonance imaging (HR-MRI) characteristics in patients with spontaneous unruptured cervicocranial arterial dissection (CCAD) before and after drug treatment. **Methods** The data of 30 CCAD patients who were diagnosed in The First Affiliated Hospital of Naval Medical University (Second Military Medical University) from Aug. 2015 to Dec. 2022 and underwent HR-MRI before and after drug treatment were retrospectively and continuously collected. According to the improvement of the stenosis of dissecting vessels on magnetic resonance angiography (MRA) at follow-up, the patients were divided into improvement group (the patients who had a reduction of 1 grade or more in the lumen stenosis at follow-up compared with baseline) and unimprovement group (the patients who had an increase of 1 grade or more or no change in the lumen stenosis at follow-up compared with baseline). The differences in clinical data of patients in the improvement group and unimprovement group, as well as the lumen and wall characteristics of HR-MRI before and after treatment, were analyzed. **Results** A total of 30 dissections were found in the 30 CCAD patients, including 14 in the improvement group (11 completely returned to normal and 3 improved in the lumen stenosis) and 16 in the unimprovement group. The age of patients in the improvement group was significantly younger than that in the unimprovement group [(37.86±9.83) years old vs [56.94±9.86] years old, $P=0.001$], and there were no significant differences in other clinical characteristics (all $P>0.05$). At baseline, in the improvement

[收稿日期] 2023-03-19 **[接受日期]** 2023-04-25

[基金项目] 国家自然科学基金(82202126),上海市自然科学基金(22ZR1478100),上海市科学技术委员会医学创新研究专项(22Y11911200). Supported by National Natural Science Foundation of China (82202126), Natural Science Foundation of Shanghai (22ZR1478100), and Medical Innovation Research Project of Science and Technology Commission of Shanghai Municipality (22Y11911200).

[作者简介] 李 帅, 主治医师. E-mail: coollee1314@163.com; 李澌, 硕士, 主治医师. E-mail: lsc_ajz@126.com

[△]共同第一作者(Co-first authors).

*通信作者(Corresponding author). Tel: 021-31162153, E-mail: zhangxf0622@126.com

group the proportion of intramural hematoma was higher and the lumen stenosis was relatively mild, while in the unimprovement group the lumen stenosis was severe, and the intimal flap, double lumen sign and pseudolumen thrombosis were more common (all $P < 0.05$). At follow-up, intramural hematoma and the degree of lumen stenosis in the improvement group were significantly improved, while there were still many residual intramural hematoma, intimal flap, double lumen sign, and pseudolumen thrombus in the unimprovement group (all $P < 0.05$). At baseline, there was no significant difference in the enhancement of the dissection vessel wall between the 2 groups ($P > 0.05$). At follow-up, the enhancement of the dissection vessel wall in the improvement group was significantly decreased compared with the unimprovement group ($P < 0.001$). **Conclusion** HR-MRI can be used to evaluate the morphological changes of the lumen and wall of CCAD before and after drug treatment. Patients with younger age and relatively mild lumen stenosis at baseline can achieve better outcomes after drug treatment.

[**Key words**] cervicocranial arterial dissection; high-resolution magnetic resonance imaging; anticoagulants; antiplatelet drug; prognosis; youth stroke

[Acad J Naval Med Univ, 2023, 44(6): 679-685]

头颈动脉夹层 (cervicocranial arterial dissection, CCAD) 是中青年缺血性脑卒中的重要病因之一^[1-3]。CCAD 是由于动脉内膜与中膜突然撕裂, 动脉管腔中的血流进入动脉管壁内造成壁内血肿, 或由于内膜与中膜内的滋养小动脉破裂形成壁内血肿。根据撕裂深度的不同, CCAD 在血管造影图像上可以表现出不同的管腔形态, 如扩张、狭窄并扩张 (串珠征)、狭窄无扩张^[4], 常规计算机断层扫描血管成像 (computed tomography angiography, CTA)、磁共振血管成像 (magnetic resonance angiography, MRA)、数字减影血管造影 (digital subtraction angiography, DSA) 检查有时难以与动脉粥样硬化、动脉炎等血管疾病相鉴别, 而高分辨率磁共振成像 (high-resolution magnetic resonance imaging, HR-MRI) 不但可以观察血管腔形态, 而且可显示病变管壁全貌, 通过 HR-MRI 评估 CCAD 更有优势^[5-6]。已有较多文献报道了急慢性期 CCAD 的 HR-MRI 表现^[7-10], 但对比观察同一病例治疗前后的 HR-MRI 影像特征变化鲜见报道。本研究回顾性分析了 30 例 CCAD 患者药物治疗前后的 HR-MRI 影像特征变化, 以更好地了解自发性未破裂 CCAD 的自然病程。

1 资料和方法

1.1 病例资料 回顾性连续收集 2015 年 8 月至 2022 年 12 月于海军军医大学 (第二军医大学) 第一附属医院脑血管病内、外科确诊为 CCAD 并在药物治疗前后行 HR-MRI 检查的 30 例患者资料。纳入标准: (1) 根据临床症状及影像学检查 (CTA、MRA、DSA 或 HR-MRI) 结果诊断为 CCAD 的患者; (2) 患者自临床症状出现至基线 HR-MRI 检

查的时间间隔 < 60 d, 即患者处于夹层急性期或亚急性期; (3) 患者确诊后行药物保守治疗, 未行手术治疗, 药物保守治疗方案为抗凝剂 (华法林) 或抗血小板药物 (阿司匹林及氯吡格雷)。排除标准: (1) 临床提示破裂的 CCAD, 如发生蛛网膜下腔出血; (2) 临床资料不全, 无法确定发病时间; (3) 患者配合不佳, 影像学图像质量差, 不能用于诊断评估。记录患者的临床资料, 包括年龄、性别、发病时临床表现、治疗经过、HR-MRI 基线检查时间和随访复查时间, 以及是否有高血压、高脂血症、糖尿病、吸烟、饮酒等。根据自临床症状出现至基线 HR-MRI 检查的时间间隔, 将患者病程分期分为急性期 (0~3 d)、亚急性早期 (4~10 d)、亚急性晚期 (11~60 d) 和慢性期 (> 60 d)^[6]。

1.2 MRI 检查方法 2 例患者的治疗前后 2 次 HR-MRI 检查在 Signa HDxt 3.0 T 磁共振仪 (美国 GE 公司) 上进行。(1) HR-MRI 血管腔成像: 采用 3D 时间飞跃法 (time-of-flight, TOF) 对颅内血管进行 MRA 检查, 用以定位夹层动脉瘤的部位。3D-TOF-MRA 扫描参数: 重复时间 (repetition time, TR) 为 29 ms, 回波时间 (echo time, TE) 为 3.4 ms, 视野为 24 cm \times 21.6 cm, 矩阵为 384 \times 192, 扫描时间为 4 min 47 s。(2) HR-MRI 血管壁成像: 采用 2D 高分辨率、抑制血流的形态学成像序列, 包括 T1 加权成像 (T1 weighted imaging, T1WI)、T2 加权成像 (T2 weighted imaging, T2WI)、注射造影剂钆喷酸葡胺后的增强 T1WI。根据 3D-TOF-MRA 图像定位扫描序列。T1WI 扫描参数: TR 为 581 ms, TE 为 20 ms, 视野为 10 cm \times 10 cm, 矩阵为 320 \times 256, 回波链长度 (echo train length, ETL) 为 6, 层数为 12, 层厚为 2.0 mm, 扫

描时间为5 min。T2WI扫描参数:TR为2 884 ms,TE为51 ms,视野为10 cm×10 cm,矩阵为320×256,ETL为20,层数为12,层厚为2.0 mm,扫描时间为3 min 51 s。造影剂钆喷酸葡胺注射剂量为0.2 mmol/kg,注射速率为2 mL/s,注射造影剂后立即进行T1WI增强扫描,扫描参数同T1WI平扫。

28例患者的治疗前后2次HR-MRI检查在MAGNETOM Skyra 3.0 T磁共振仪(德国Siemens公司)上进行。(1)HR-MRI血管腔成像:进行3D-TOF-MRA扫描,图像用于显示血管腔及定位2D T2WI序列夹层动脉瘤部位。扫描参数:TR为21 ms,TE为3.4 ms,视野为18.1 cm×19.9 cm,矩阵为662×768,扫描时间为4 min 40 s。(2)HR-MRI血管壁成像,包括2D T2WI、矢状面3D可变翻转角快速自旋回波(3D-sampling perfection with application optimized contrast using different flip angle evolutions, 3D-SPACE) T2WI、3D-SPACE T1WI。根据3D-TOF-MRA图像定位2D T2WI序列垂直病变段夹层动脉瘤血管。2D T2WI扫描参数:TR为2 890 ms,TE为55 ms,视野为10 cm×10 cm,矩阵为256×320,ETL为20,层厚为2.0 mm,层数为16,扫描时间为3 min 40 s。3D-SPACE T2WI扫描参数:TR为1 500 ms,TE为149 ms,视野为16 cm×25 cm,矩阵为268×448,ETL为78,层厚为0.6 mm,层数为224,扫描时间为5 min 57 s。3D-SPACE T1WI扫描参数:TR为800 ms,TE为16 ms,视野为16 cm×25 cm,矩阵为273×448,ETL为60,层厚为0.6 mm,层数为224,扫描时间为6 min 22 s。(3)3D-MRA检查:注射造影剂钆喷酸葡胺后进行3D-MRA检查,钆喷酸葡胺注射剂量为0.2 mmol/kg,注射速率为3 mL/s,行增强前、增强后动脉期与静脉期3次扫描,每次扫描时间约16.07 s。扫描参数:TR为3.5 ms,TE为1.2 ms,视野为31.5 cm×42 cm,矩阵为230×384,ETL为0,层厚为1.1 mm,层数为104。3D-MRA序列扫描结束后立即行HR-MRI T1WI增强扫描,扫描参数同3D-SPACE T1WI平扫。

1.3 图像分析 由2名从事血管疾病影像诊断的高年资医师在影像存储与传输系统ADW4.4工作站(美国GE公司)共同完成图像分析。

(1)动脉夹层管腔狭窄程度评估:按照北美症状性颈动脉内膜剥脱试验(North American

Symptomatic Carotid Endarterectomy Trial)血管狭窄率计算方法,在MRA图像上测量夹层动脉真腔内径,计算颅外颈内动脉、椎动脉狭窄率:狭窄率(%)=(1-最窄处直径/狭窄远端正常直径)×100%^[11]。根据MRA图像测量夹层动脉真腔内径,根据华法林-阿司匹林症状性颅内动脉疾病试验(Warfarin-Aspirin Symptomatic Intracranial Disease Study)方法计算颅内动脉狭窄率:狭窄率(%)=(1-最窄处直径/狭窄近端正常直径)×100%,如近端有病变则用远端正常血管代替^[12]。按狭窄率将血管狭窄程度分为5级:1级为正常;2级为轻度狭窄,狭窄率<50%;3级为中度狭窄,狭窄率为50%~69%;4级为重度狭窄,狭窄率为70%~99%;5级为完全闭塞。根据基线及随访MRA图像上的管腔形态变化情况,将患者分为改善组与未改善组。随访时夹层血管管腔狭窄程度与基线对比狭窄减轻达1个级别及以上的患者纳入改善组,狭窄程度加重1个级别及以上或无变化者纳入未改善组。

(2)壁内血肿及腔内血栓形成:壁内血肿在T1WI、T2WI平扫或T1WI增强扫描图像上被评定为充满血肿而无血液流动的假腔,壁内血肿横断面显示为新月形、环形或类圆形改变,通常无明显强化;腔内血栓形成是真腔或假腔内的条状或不规则形不均匀信号影,增强后有强化。

(3)血管壁强化:在T1WI增强扫描图像上对血管壁强化程度进行分级,并根据视觉分级系统评价强化程度:0级,与正常血管壁强化程度相似;1级,高于0级,但低于肌肉强化程度或与之相似;2级,高于肌肉强化程度^[7]。

1.4 统计学处理 应用SPSS 19.0软件进行统计学分析。采用Kolmogorov-Smirnov检验分析计量资料是否符合正态分布,符合正态分布的计量资料以 $\bar{x}\pm s$ 表示,采用独立样本 t 检验进行比较;不符合正态分布的计量资料以中位数(下四分位数,上四分位数)表示,采用Mann-Whitney U 检验进行比较。计数资料以例数和百分数表示,用行×列表 χ^2 检验或Fisher确切概率法进行比较。等级资料以例数和百分数表示,采用Mann-Whitney U 检验进行比较。检验水准(α)为0.05。

2 结果

2.1 患者临床特征 30例CCAD患者中男23例、

女7例,年龄为(48.03±13.67)岁(26~75岁),基线与随访HR-MRI检查的时间间隔为126(74,225)d。30例CCAD患者共计30处夹层,其中椎动脉夹层14例,椎基底动脉夹层3例,基底动脉夹层2例,颈内动脉夹层9例,大脑中动脉夹层2例。药物保守治疗后30例患者均未见新发夹层。30例患者临床表现为脑梗死24例,短暂性脑缺血发作4例,头痛1例,颈部疼痛1例。基线病程分期急性期患者3例,亚急性早期14例,亚急性晚

期13例;随访时30例患者均为慢性期。既往史包括高血压(14例)、吸烟史(6例)、糖尿病(6例)和高脂血症(2例)。根据基线及随访MRA图像上夹层血管管腔的形态变化情况,30例CCAD患者中改善组14例,未改善组16例,改善组患者的年龄小于未改善组($t=-5.297, P=0.001$),其余临床特征差异均无统计学意义(P 均 >0.05),见表1。

表1 改善组与未改善组CCAD患者临床特征比较

Tab 1 Comparison of clinical characteristics of CCAD patients between improvement and unimprovement groups

Characteristic	Improvement group N=14	Unimprovement group N=16	Statistic	P value
Gender, n (%)			$\chi^2=1.139$	0.286
Male	9 (64.3)	14 (87.5)		
Female	5 (35.7)	2 (12.5)		
Age/year, $\bar{x} \pm s$	37.86±9.83	56.94±9.86	$t=-5.297$	0.001
Stroke, n (%)	12 (85.7)	16 (100.0)	$\chi^2=0.691$	0.209
Hypertension, n (%)	4 (28.6)	10 (62.5)	$\chi^2=2.225$	0.081
Diabetes mellitus, n (%)	1 (7.1)	5 (31.2)	$\chi^2=1.415$	0.175
Smoking, n (%)	1 (7.1)	5 (31.2)	$\chi^2=1.415$	0.175
Hyperlipemia, n (%)	1 (7.1)	1 (6.2)	$\chi^2=0.000$	1.000
Antiplatelet drug use, n (%)	12 (85.7)	11 (68.8)	$\chi^2=0.132$	0.651
Warfarin use, n (%)	2 (14.3)	3 (18.8)	$\chi^2=0.000$	1.000
Stage of dissection, n (%)			$\chi^2=4.102$	0.129
Acute	0	3 (18.8)		
Early subacute	7 (50.0)	7 (43.8)		
Late subacute	7 (50.0)	6 (37.5)		
Dissection location, n (%)			$\chi^2=4.102$	0.129
ICA	5 (35.7)	4 (25.0)		
MCA	1 (7.1)	1 (6.2)		
VA	8 (57.1)	6 (37.5)		
VA-BA	0	3 (18.8)		
BA	0	2 (12.5)		
Interval from baseline to follow-up/d, $M(Q_L, Q_U)$	134 (78, 213)	120 (64, 276)	$Z=-0.437$	0.667

Improvement group: The patients had a reduction of 1 grade or more in the lumen stenosis at follow-up compared with baseline; Unimprovement group: The patients had an increase of 1 grade or more or no change in the lumen stenosis at follow-up compared with baseline. CCAD: Cervicocranial arterial dissection; ICA: Internal carotid artery; MCA: Middle cerebral artery; VA: Vertebral artery; BA: Basilar artery; $M(Q_L, Q_U)$: Median (lower quartile, upper quartile).

2.2 夹层治疗前后管腔及管壁特征 经保守治疗后,改善组14例患者中有11例患者管腔狭窄完全恢复正常,3例狭窄程度有所改善;未改善组16例患者中15例患者管腔狭窄无变化,1例狭窄进展。改善组与未改善组基线及随访时HR-MRI特征表现见表2。改善组患者基线壁内血肿比例与未改善组相比较高($P=0.007$),管腔狭窄程度相对较轻($P=0.025$);而未改善组夹层内膜瓣与双腔征、假腔内血栓形成较改善组更常见($P=0.046$ 、

0.001)。治疗后随访时,改善组壁内血肿、管腔狭窄程度与未改善组相比均改善($P=0.017$ 、 <0.001),而未改善组夹层内膜瓣与双腔征、假腔内血栓相较于改善组仍有较多残留($P=0.001$ 、 0.001)。两组基线夹层血管壁强化程度差异无统计学意义($P=0.759$),随访时改善组患者血管壁强化程度降低且与未改善组相比差异有统计学意义($P<0.001$)。改善组患者典型影像学表现见图1。

表 2 改善组与未改善组 CCAD 患者 HR-MRI 特征比较

Tab 2 Comparison of HR-MRI characteristics of CCAD patients between improvement and unimprovement groups

Characteristic	Improvement group N=14	Unimprovement group N=16	n (%)	
			Statistic	P value
Baseline intramural hematoma	14 (100.0)	9 (56.2)	$\chi^2=5.731$	0.007
Follow-up intramural hematoma	1 (7.1)	8 (50.0)	$\chi^2=4.649$	0.017
Baseline intimal flap and double lumen	7 (50.0)	14 (87.5)	$\chi^2=3.374$	0.046
Follow-up intimal flap and double lumen	2 (14.3)	14 (87.5)	$\chi^2=13.274$	0.001
Baseline pseudolumen thrombosis	1 (7.1)	11 (68.8)	$\chi^2=9.381$	0.001
Follow-up pseudolumen thrombosis	0	11 (68.8)	$\chi^2=12.381$	0.001
Baseline grade of stenosis			Z=-2.469	0.025
Mild	1 (7.1)	1 (6.2)		
Moderate	1 (7.1)	0		
Severe	10 (71.4)	5 (31.2)		
Occlusion	2 (14.3)	10 (62.5)		
Follow-up grade of stenosis			Z=-4.823	<0.001
Normal	11 (78.6)	0		
Mild	2 (14.3)	1 (6.2)		
Moderate	1 (7.1)	0		
Severe	0	4 (25.0)		
Occlusion	0	11 (68.8)		
Baseline grade of vessel wall enhancement			Z=-1.069	0.759
0	1 (7.1)	0		
1	0	0		
2	13 (92.9)	16 (100.0)		
Follow-up grade of vessel wall enhancement			Z=-3.966	<0.001
0	11 (78.6)	1 (6.2)		
1	0	0		
2	3 (21.4)	15 (93.8)		

Improvement group: The patients had a reduction of 1 grade or more in the lumen stenosis at follow-up compared with baseline; Unimprovement group: The patients had an increase of 1 grade or more or on change in the lumen stenosis at follow-up compared with baseline. CCAD: Cervicocranial arterial dissection; HR-MRI: High-resolution magnetic resonance imaging.

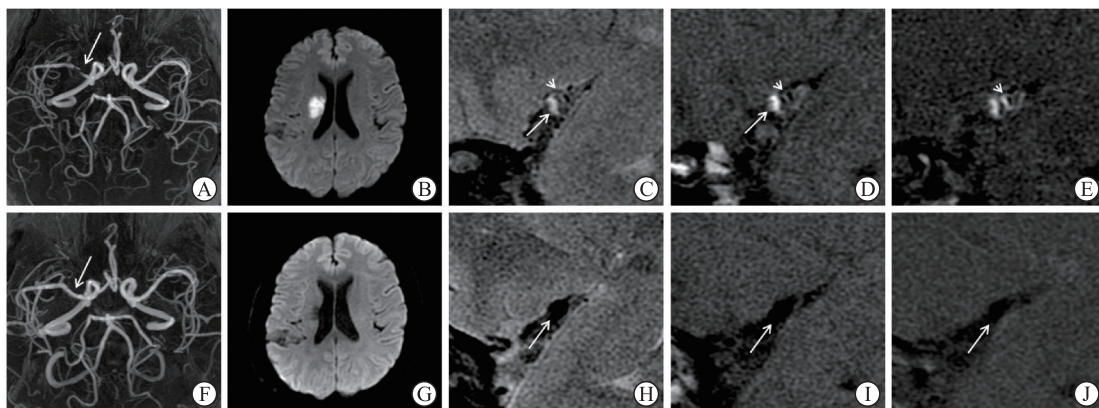


图 1 改善组 1 例大脑中动脉夹层患者药物治疗前后 HR-MRI 特征表现

Fig 1 HR-MRI characteristics of a patient with middle cerebral artery dissection before and after drug treatment in improvement group

Female, 44 years old. The patient presented with sudden angular deviation and numbness and weakness in her left limb. A-E: The baseline images before treatment. A: 3D-TOF-MRA showing severe stenosis of the M1 segment of the right middle cerebral artery (arrow). B: DWI showing acute cerebral infarction beside the right lateral ventricle. C-E: HR-MRI vessel wall imaging showing formation of dissection of the M1 segment of the right middle cerebral artery. T2WI (C) and T1WI (D) plain scans showed that intimal flap (short arrows), true lumen, false lumen, and intramural hematoma (long arrows) were seen in the inner wall of the false lumen. On CE-T1WI (E) vessel wall image, enhancement was seen in the intimal flap (arrow). F-J: The reexamined images after 1 year of conservative drug treatment. F: 3D-TOF-MRA showing a significant improvement in the stenosis of the M1 segment of the right middle cerebral artery (arrow). G: DWI showing an old cerebral infarction near the right lateral ventricle. HR-MRI T2WI (H), T1WI (I), and CE-T1WI (J) vessel wall imaging showed that the lumen morphology of the right middle cerebral artery was completely recovered, without residual dissection (arrows). HR-MRI: High-resolution magnetic resonance imaging; 3D-TOF-MRA: 3D time-of-flight magnetic resonance angiography; DWI: Diffusion weighted imaging; T2WI: T2 weighted imaging; T1WI: T1 weighted imaging; CE-T1WI: Contrast enhanced-T1 weighted imaging.

3 讨论

本研究观察了30例CCAD患者药物治疗前后HR-MRI特征变化,结果显示通过HR-MRI可对CCAD药物治疗前后的管腔及管壁形态学特征进行评估,HR-MRI可显示夹层血管管腔再通、管腔狭窄程度、壁内血肿、腔内血栓形成及血管壁强化等信息,年龄小、基线管腔狭窄程度相对较轻的患者经药物治疗后夹层恢复较好。

CCAD临床表现差异大,可从无症状、轻微颈部疼痛到严重神经症状,临床诊断具有挑战性。HR-MRI是可在活体上显示颅内动脉管壁病变的无创影像学方法,其能对夹层动脉瘤直接进行动脉管腔和管壁评估,显示动脉夹层内膜瓣、双腔征、壁内血肿、腔内血栓形成及相邻组织受压情况,极大提高了CCAD的诊断准确性^[5-6]。内膜瓣及双腔征是诊断动脉夹层的直接征象^[11]。本组病例内膜瓣及双腔征检出率为70.0%(21/30)。动脉粥样硬化、动脉夹层、烟雾病、血管炎、动脉血栓栓塞、动脉先天发育不良等均可造成血管造影动脉管腔狭窄或闭塞表现,通过HR-MRI可进行病因鉴别,管腔中发现内膜瓣及双腔征即可明确动脉夹层诊断。

壁内血肿是夹层的另一特征性表现^[13]。在HR-MRI图像上壁内血肿根据T1WI和T2WI的信号差别可分为急性血肿、早期亚急性血肿、晚期亚急性血肿和慢性血肿,考虑到短暂性脑缺血发作或脑梗死复发风险在CCAD发生后的2~3周最高,因此急性血肿比慢性血肿患者需要更密切的临床观察。通过HR-MRI图像上血肿的信号表现可对初始没有特异性临床症状的动脉夹层患者进行发病时间判别,从而获得正确的诊断,以便选择合适的治疗方案或随访策略。

动脉夹层血管壁强化的机制尚不完全清楚,血管壁内的任何损伤或炎症都可能导致强化。治疗后管腔狭窄程度改善的CCAD患者血管壁强化可降低或恢复正常,而管腔或管壁形态无恢复的患者在慢性期管壁仍可持续强化。本研究中治疗前改善组与未改善组30处夹层中29处有强化,治疗后随访时改善组患者血管壁强化程度降低($P<0.001$),而未改善组患者随访时血管壁强化程度仍然较高(93.8%,15/16)。慢性期持续性血管壁强化也可能与愈合过程中内膜增生、肉芽组织或滋养血

管强化有关。Jung等^[8]对慢性期夹层进行研究发现,即使在管腔血管造影完全恢复正常的情况下,HR-MRI也可以检测到病灶处血管壁增厚并强化,认为在夹层愈合过程中假腔周围发生代偿性内膜增生^[14]会导致血管壁强化。

未破裂CCAD具有自愈倾向,研究显示在发病最初2个月37.4%~75.0%的患者表现为自发改善^[15-16],夹层的HR-MRI特征表现(如内膜瓣、双腔征、壁内血肿、假腔血栓形成、管壁强化等)也会随着时间进程而发生改变^[6-7,17]。Jung等^[8]将慢性期颅内动脉夹层依据血管造影(MRA、CTA和DSA)及HR-MRI形态表现分为完全正常化、完全正常化伴微小管壁改变、不完全正常化、夹层动脉瘤和闭塞。本研究中30处夹层经药物治疗后随访时均为夹层慢性期,亦可以观察到Jung等^[8]描述的夹层形态学表现。夹层动脉瘤在愈合过程中,壁内血肿内炎症细胞浸润、巨噬细胞活跃,最终被肉芽组织取代。夹层最早的修复过程似乎是假腔内的壁内血肿被肉芽组织取代,紧随其后是内膜增生,这是对损伤的一种代偿反应。当内膜增厚到足以克服夹层破裂处的血流动力学应力时,增厚的内膜内新生血管生成或许就开始了,最早可以在发病后30d开始。在未破裂的颅内动脉夹层患者中,83.9%的患者在发病后2周至2个月可出现血管形态的几何改变,其中61.5%和18.3%的患者分别表现为放射学改善和完全正常化^[3],而本组病例的中位随访时间为126d,放射学改善和完全正常化的比例分别为46.7%(14/30)和36.7%(11/30)。

本研究对30处夹层进行随访发现,CCAD的病程演变依赖于最初的管腔形态及患者年龄。未改善组患者的年龄较改善组高,年龄越大提示夹层患者合并动脉粥样硬化等高风险的可能性越大。Chun等^[18]对有无合并动脉粥样硬化的夹层预后差异进行研究,合并动脉粥样硬化的夹层患者年龄相对较大,血管受累更广泛,治疗后3个月和1年功能恢复较差。另外,本研究结果显示基线时管腔狭窄相对较轻的CCAD患者药物治疗后夹层恢复好。这与Ahn等^[4]对自发性症状性颅内椎基底动脉夹层进行造影随访的结果相仿,该随访研究显示最常见的放射学改善特征是管腔狭窄无扩张的夹层病变。合并管腔狭窄的夹层大多伴有壁内血肿,壁内血肿可随着时间的推移而吸收、消失、回缩,

最终可能在慢性期消退,本研究中改善组有14例患者夹层可以观察到壁内血肿,经治疗后随着壁内血肿吸收管腔狭窄明显改善,11例表现为夹层完全恢复正常,而未改善组CCAD中内膜瓣、双腔征及假腔内血栓形成比例高,夹层吸收缓慢,尚需延长随访时间以进一步观察未改善组夹层变化情况。本研究结果提示伴有壁内血肿并表现为管腔狭窄的CCAD患者经药物保守治疗后临床预后好,可以避免早期介入手术治疗。

本研究存在以下局限性:(1)样本量小且为回顾性研究,存在选择偏倚;(2)CCAD管腔形态学表现分为狭窄无扩张、扩张、狭窄并扩张,而本研究纳入的30例患者均为狭窄无扩张的夹层病例;(3)病例基线至随访HR-MRI检查的时间间隔差异大,不同随访时间间隔与夹层预后差异的关系需长期多次随访研究进一步明确。

[参考文献]

- [1] EKKER M S, BOOT E M, SINGHAL A B, TAN K S, DEBETTE S, TULADHAR A M, et al. Epidemiology, aetiology, and management of ischaemic stroke in young adults[J]. *Lancet Neurol*, 2018, 17: 790-801.
- [2] WU Y J, CHEN H B, XING S H, TAN S Q, CHEN X R, TAN Y, et al. Predisposing factors and radiological features in patients with internal carotid artery dissection or vertebral artery dissection[J/OL]. *BMC Neurol*, 2020, 20: 445. DOI: 10.1186/s12883-020-02020-8.
- [3] CLARK M, UNNAM S, GHOSH S. A review of carotid and vertebral artery dissection[J]. *Br J Hosp Med (Lond)*, 2022, 83: 1-11.
- [4] AHN S S, KIM B M, SUH S H, KIM D J, KIM D I, SHIN Y S, et al. Spontaneous symptomatic intracranial vertebrobasilar dissection: initial and follow-up imaging findings[J]. *Radiology*, 2012, 264: 196-202.
- [5] ZHU X J, QIU H C, HUI F K, ZHANG Y Q, LIU Y E, MAN F Y, et al. Practical value of three-dimensional high resolution magnetic resonance vessel wall imaging in identifying suspicious intracranial vertebrobasilar dissecting aneurysms[J/OL]. *BMC Neurol*, 2020, 20: 199. DOI: 10.1186/s12883-020-01779-0.
- [6] SHI Z, TIAN X, TIAN B, MEDDINGS Z, ZHANG X F, LI J, et al. Identification of high risk clinical and imaging features for intracranial artery dissection using high-resolution cardiovascular magnetic resonance[J/OL]. *J Cardiovasc Magn Reson*, 2021, 23: 74. DOI: 10.1186/s12968-021-00766-9.
- [7] PARK K J, JUNG S C, KIM H S, CHOI C G, KIM S J, LEE D H, et al. Multi-contrast high-resolution magnetic resonance findings of spontaneous and unruptured intracranial vertebral artery dissection: qualitative and quantitative analysis according to stages[J]. *Cerebrovasc Dis*, 2016, 42: 23-31.
- [8] JUNG S C, KIM H S, CHOI C G, KIM S J, KWON S U, KANG D W, et al. Spontaneous and unruptured chronic intracranial artery dissection: high-resolution magnetic resonance imaging findings[J]. *Clin Neuroradiol*, 2018, 28: 171-181.
- [9] JUNG S C, KIM H S, CHOI C G, KIM S J, LEE D H, SUH D C, et al. Quantitative analysis using high-resolution 3 T MRI in acute intracranial artery dissection[J]. *J Neuroimaging*, 2016, 26: 612-617.
- [10] YUN S Y, HEO Y J, JEONG H W, BAEK J W, CHOO H J, SEO J H, et al. Spontaneous intracranial vertebral artery dissection with acute ischemic stroke: high-resolution magnetic resonance imaging findings[J]. *Neuroradiol J*, 2018, 31: 262-269.
- [11] WU Y, WU F, LIU Y H, FAN Z Y, FISHER M, LI D B, et al. High-resolution magnetic resonance imaging of cervicocranial artery dissection: imaging features associated with stroke[J]. *Stroke*, 2019, 50: 3101-3107.
- [12] CHIMOWITZ M I, KOKKINOS J, STRONG J, BROWN M B, LEVINE S R, SILLIMAN S, et al. The warfarin-aspirin symptomatic intracranial disease study[J]. *Neurology*, 1995, 45: 1488-1493.
- [13] HABS M, PFEFFERKORN T, CYRAN C C, GRIMM J, ROMINGER A, HACKER M, et al. Age determination of vessel wall hematoma in spontaneous cervical artery dissection: a multi-sequence 3 T cardiovascular magnetic resonance study[J/OL]. *J Cardiovasc Magn Reson*, 2011, 13: 76. DOI: 10.1186/1532-429X-13-76.
- [14] ONO H, NAKATOMI H, TSUTSUMI K, INOUE T, TERAOKA A, YOSHIMOTO Y, et al. Symptomatic recurrence of intracranial arterial dissections: follow-up study of 143 consecutive cases and pathological investigation[J]. *Stroke*, 2013, 44: 126-131.
- [15] KIM B M, KIM S H, KIM D I, SHIN Y S, SUH S H, KIM D J, et al. Outcomes and prognostic factors of intracranial unruptured vertebrobasilar artery dissection[J]. *Neurology*, 2011, 76: 1735-1741.
- [16] ARAUZ A, MÁRQUEZ J M, ARTIGAS C, BALDERRAMA J, ORREGO H. Recanalization of vertebral artery dissection[J]. *Stroke*, 2010, 41: 717-721.
- [17] NAGAHATA M, MANABE H, HASEGAWA S, TAKEMURA A. Morphological change of unruptured vertebral artery dissection on serial MR examinations. evaluation of the arterial outer contour by basi-parallel anatomical scanning (BPAS)-MRI[J]. *Neurohospitalist*, 2006, 12: 133-136.
- [18] CHUN C E, CHANG F C, HUANG H C, JUI-YAO T, CHIH-PING C. Characteristics and outcomes of vertebrobasilar artery dissection with accompanied atherosclerosis[J]. *Cerebrovasc Dis Extra*, 2017, 7: 165-172.