

DOI:10.3724/SP.J.1008.2013.01253

一种应用经皮冠状动脉成形术导丝在经桡动脉介入治疗中置入鞘管及导管的方法

张志钢[△], 张必利[△], 刘宇, 秦永文, 赵仙先*

第二军医大学长海医院心血管内科, 上海 200433

[摘要] **目的** 探讨经桡动脉介入治疗(transradial intervention, TRI)过程中应用经皮冠状动脉成形术(percutaneous transluminal coronary angioplasty, PTCA)导丝置入鞘管及完成冠状动脉造影的安全性及有效性。**方法** 2012年1月至2013年3月行TRI的病例中,术前Allen试验阳性、Seldinger法穿刺桡动脉后穿刺套管回血满意但无法置入直导丝的21例患者,经套管将PTCA导丝送至锁骨下动脉处,置入6F桡动脉鞘管,经PTCA导丝推送5F造影导管至肱动脉,交换导丝完成冠状动脉造影。术后即刻拔除鞘管,观察术后即刻至术后3d血管穿刺相关并发症(出血、血肿、迷走反射、假性动脉瘤)发生情况。**结果** 所有21例患者均成功应用PTCA导丝(Runthrough NS导丝)置入动脉鞘管,完成冠状动脉造影,12例(57.1%)患者随后完成经桡动脉PTCA及植入冠脉支架治疗,其中1例发生桡动脉痉挛。所有患者术后即刻造影显示无造影剂外渗,术后即刻至术后3d内无穿刺点出血、前臂血肿、迷走反射及假性动脉瘤,术后监测血压良好。**结论** 桡动脉穿刺时穿刺针或套管回血满意、直导丝无法置入时,可应用PTCA导丝通过前臂血管成功置入动脉鞘管完成冠脉造影。该方法安全、有效,提高了桡动脉穿刺成功率,可作为桡动脉穿刺时的一种备选方法。

[关键词] 经皮冠状动脉介入术;冠状血管造影术;桡动脉;并发症**[中图分类号]** R 540.4 **[文献标志码]** A **[文章编号]** 0258-879X(2013)11-1253-04

Application of percutaneous transluminal coronary angioplasty guidewire in introducing artery sheath and catheter during transradial intervention

ZHANG Zhi-gang[△], ZHANG Bi-li[△], LIU Yu, QIN Yong-wen, ZHAO Xian-xian*

Department of Cardiovasology, Changhai Hospital, Second Military Medical University, Shanghai 200433, China

[Abstract] **Objective** To apply percutaneous transluminal coronary angioplasty (PTCA) guidewire (0.014 inch, 1 inch=2.54 cm) for introducing a sheath, and to assess its safety and efficacy in completing the transradial percutaneous coronary intervention (PCI). **Methods** Twenty-one patients were included in this study. They were scheduled to undergo elective coronary intervention via the radial artery from January 2012 to March 2013, with normal Allen's test results, but the straight guidewire (0.025 inch) failed to be inserted through the needle after successful puncture of radial artery via Seldinger technique. Then a PTCA guidewire was used to gently access the radial artery instead of the straight guidewire to the brachial artery; the needle was removed and a 6F sheath was introduced into the radial artery over the PTCA guidewire, and the 5F coronary angiography catheter was advanced to the brachial artery, replacing the PTCA guidewire with a guidewire (0.035 inch). Then the angiography was completed, and the artery sheath was removed immediately after PCI. The access site-related complications including hematomas, perforation, pseudoaneurysm, and vasovagal reaction were observed immediately after operation and for 3 days. **Results** The 6F sheath were advanced into the radial artery over the PTCA guidewire in all the 21 cases and coronary angiography were successfully completed. And coronary intervention was performed in twelve (57.1%) patients, with one patient having radial artery spasm. No extravasation of contrast media was noted immediately after operation; no vascular complications (access site bleeding, hematomas, pseudoaneurysm, and vasovagal reaction) were noted 3 days after operation; and the patients had a normal blood pressure after operation. **Conclusion** When the radial artery is successfully punctured and a

[收稿日期] 2013-05-31**[接受日期]** 2013-07-10**[作者简介]** 张志钢, 博士生, 主治医师. E-mail: zhangzg@163.com; 张必利, 博士, 主治医师. E-mail: zbli0026@sina.com[△]共同第一作者(Co-first authors).

* 通信作者(Corresponding author). Tel: 021-31161265, E-mail: 13601713431@163.com

straight guidewire (0.025 inch) failed to be inserted, PTCA guidewire can be used instead to deliver the sheath to complete PCI. The method is safe, effective, and can increase the success rate of puncture of the radial artery and therefore may be an alternative for radial artery puncture.

[Key words] percutaneous coronary intervention; coronary angiography; radial artery; complications

[Acad J Sec Mil Med Univ, 2013, 34(11):1253-1256]

经桡动脉途径进行心血管介入治疗(transradial intervention, TRI)已经在我国广泛开展,桡动脉穿刺的成败是能否进行 TRI 的首要条件,穿刺时会遇到穿刺针或套管回血满意但导丝无法置入的情况,调整穿刺针或穿刺套管方向、角度后仍较难成功置入导丝而不得不重新穿刺,此时初次穿刺造成的局部血肿或痉挛增加再次穿刺难度,常导致穿刺失败而被迫改行股动脉穿刺,增加患者痛苦,延长手术时间^[1-2]。在临床实践中,我们应用经皮冠状动脉成形术(percutaneous transluminal coronary angioplasty, PTCA)指引导丝处理上述情况,成功完成冠状动脉造影,避免了经桡动脉途径操作失败及局部血管并发症的出现,具有临床实用性,现将该方法总结如下。

1 资料和方法

1.1 病例选择 2012 年 1 月至 2013 年 3 月在长海医院心血管内科行经桡动脉冠状动脉造影和(或)介入治疗的病例中,术前 Allen 试验阳性,穿刺后穿刺针套管回血满意但无法置入直导丝,调整穿刺针/套管方向及深浅,或再次近端穿刺后回血满意但仍无法植入直导丝的患者 21 例,其中 1 例患者在第 1 次穿刺点近端穿刺成功后仍无法置入直导丝。患者中男性 9 例,女性 12 例;年龄 52~74 岁,平均(61±13)岁;2 型糖尿病 11 例,原发性高血压 15 例。

1.2 方法

1.2.1 桡动脉穿刺及鞘管置入 患者取平卧位,常规消毒铺无菌巾,1%利多卡因局部浸润麻醉桡骨茎突上方 1 cm 处,应用 Terumo 公司桡动脉穿刺套装[20G 穿刺针、0.025 inch (1 inch=2.54 cm)直导丝及 6F 动脉鞘管]Seldinger 法穿刺桡动脉,穿刺见回血后常规推送,撤出针芯,缓慢回撤套管,动脉血“喷出”后,无法置入直导丝,轻微旋转及调整套管位置及方向,套管回血良好但仍无法成功置入直导丝,则退出直导丝,经穿刺针套管置入 PTCA 导丝(首选

Runthrough NS 导丝),前臂透视下,轻柔操作 PTCA 导丝无阻力通过前臂血管至锁骨下动脉(图 1),补充麻醉,以手术刀片充分切开皮肤约 2~3 mm,沿导丝透视下置入 6F 桡动脉鞘管及扩张鞘管,保留 PTCA 导丝,退出扩张鞘管,沿侧管注入普通肝素 5 000 U,测动脉压力无禁忌后推注硝酸甘油 200 μg。

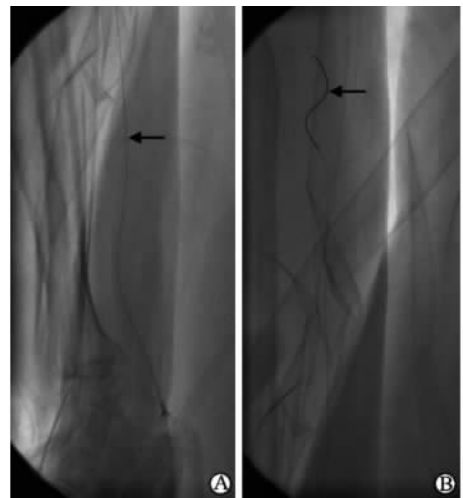


图 1 PTCA 导丝经穿刺针套管通过技术
Fig 1 Advancing percutaneous transluminal coronary angioplasty (PTCA) guidewire through the needle to forearm artery

A: Advancing PTCA guidewire (arrow) through the needle to the radial artery; B: Advancing PTCA guidewire (arrow) to the brachial artery

1.2.2 冠状动脉造影术 沿 PTCA 导丝透视下推送 5F 造影导管,必要时可接 Y 阀在推注稀释造影剂(0.9%氯化钠溶液与德国拜耳公司产碘普罗胺注射剂 1:1 稀释)的指导下通过前臂血管至肱动脉近心端,交换为 0.035 inch 泥鳅导丝或普通 J 型导丝(图 2),完成冠状动脉造影。

1.2.3 术后处理、观察及随访 术后经动脉鞘管以稀释造影剂行前臂血管造影,观察有无造影剂外渗情况;穿刺点以桡动脉压迫器加压包扎,观察穿刺点出血、前臂血肿情况及血压,术后每 2 h 减压,8 h 解

除加压包扎, 观察术后即刻至术后 3 d 血管穿刺相关并发症(出血、血肿、迷走反射、假性动脉瘤等)出现的情况; 术后根据患者病情需要常规抗血小板、抗凝, 随访 3 d。

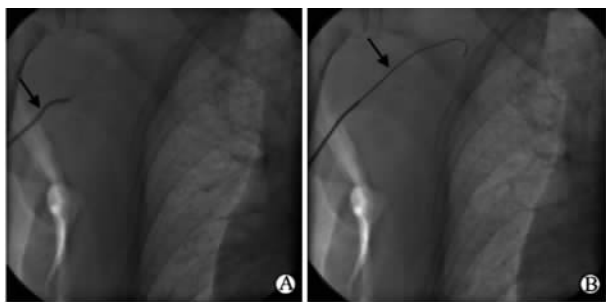

图 2 经 PTCA 导丝置入造影导管技术

Fig 2 Placing coronary angiography catheter over percutaneous transluminal coronary angioplasty (PTCA) guidewire

A: Advancing the 5F coronary angiography catheter (arrow) over the PTCA guidewire gently to the proximal portion of the brachial artery; B: Exchanging PTCA guidewire with the ordinary guidewire (0.035 inch, 1 inch=2.54 cm) (arrow)

2 结果

所有患者均成功应用 PTCA 导丝(Runthrough NS 导丝)通过前臂血管至肱动脉近心端, 交换为其他导丝后成功完成冠状动脉造影。12 例患者随后完成经桡动脉 PTCA 及植入冠脉支架治疗(57.1%), 其中 1 例发生桡动脉痉挛, 经注射硝酸甘油后缓解。所有患者术后即刻造影显示无造影剂外渗, 术后即刻至术后 3 d 未发现穿刺点出血、前臂血肿、迷走反射及假性动脉瘤, 术后监测血压良好。

3 讨论

TRI 因具有创伤小、局部血管并发症少^[3]、术后患者可早期活动、缩短住院天数、减少住院费用等优点而被广泛应用。桡动脉成功穿刺是 TRI 顺利进行的首要条件, 桡动脉管腔细, 易痉挛, 穿刺失败率为 1%~5%^[4], 高于股动脉穿刺, 操作者学习曲线较长, 一定程度上限制了 TRI 的应用。桡动脉穿刺有时会遇到 Allen 试验阳性、桡动脉搏动良好、无桡动脉痉挛的发生, 但穿刺导丝无法置入的情况^[4]。其原因可能是动脉发育不全, 但是这种情况非常罕见; 更常见的原因是桡尺环、穿刺针和动脉管壁成角过大、多次穿刺引起桡动脉痉挛、远端桡动脉迂曲、钢

丝在小的血管分支或进入血管内膜下引起夹层等^[5]。通常的处理方法为经穿刺针/套管注入稀释的造影剂明确情况后使用泥鳅导丝通过前臂血管, 但此方法反复操作有时可导致局部血肿、桡动脉痉挛, 使得再次穿刺困难, 从而只能改为经股动脉途径完成介入治疗。我中心利用 PTCA 导丝透视下经穿刺套管送入前臂血管, 将 PTCA 导丝送至右侧锁骨下动脉处, 证明导丝确实位于动脉真腔内; 送入的 PTCA 导丝头端柔软、支撑力差, 而中段部分较硬、支撑力强, 利用中段较硬部分可以顺利导入桡动脉鞘管。送入桡动脉鞘管前的补充麻醉及充分切开皮肤必不可少, 尤其是对于多次经桡动脉介入治疗的患者更为重要, 必要时可采用止血钳进行扩张, 减少推送鞘管时皮肤及皮下组织的阻力, 通过手感判断桡动脉粗细及痉挛情况, 还可避免因 PTCA 导丝直径细、支撑力欠佳而导致的入鞘困难。置入鞘管应在透视下进行, 注意观察鞘管的方向, 切忌暴力, 如阻力太大或者患者主诉疼痛明显, 没有必要将动脉鞘管全部置入, 使其进入血管腔内一定距离即可。沿 PTCA 导丝继续送入 5F 造影导管至锁骨下动脉后交换为 J 型钢丝或者泥鳅导丝即可完成冠状动脉造影。日常使用的 PTCA 导丝(如 Runthrough 导丝、BMW 导丝)均可完成上述操作, 虽然较普通 J 型导丝或泥鳅导丝支撑力差, 但是操控性及通过性较好, 头端柔软能够防止血管穿孔, 可以安全通过狭窄、痉挛及迂曲的动脉。有文献报道使用 PTCA 导丝通过异常桡动脉完成经皮冠状动脉介入治疗(percutaneous coronary intervention, PCI)^[6], 但该文献中报道的病例是在成功置入桡动脉鞘管后, 经鞘管注入解痉药物(硝酸甘油 200 μg), 然后使用 PTCA 导丝通过迂曲、痉挛的血管。而我中心则是在穿刺遇到困难时即使用 PTCA 导丝, 避免了反复穿刺, 增加了桡动脉穿刺的成功率, 也减少了改行股动脉途径的比例。

虽然使用 PTCA 导丝增加了一根 PTCA 导丝的费用, 然而若改行股动脉穿刺, 则医疗费用增加更多, 包括股动脉鞘管、左右冠脉造影导管及血管缝合器等费用, 而且易发生股动脉穿刺相关的并发症, 后续医疗费用更多。此外, 在急性心肌梗死患者直接 PCI 中经桡动脉途径具有诸多优势^[7], 对于强调

Door-to-balloon 时间的急诊手术而言,迅速建立有效的动脉途径可缩短治疗时间,并且因急性心肌梗死急诊手术患者大多需要 PTCA 导丝进行 PCI 操作,因此当穿刺针套管回血满意、直导丝无法置入时可尝试此法。当 PTCA 导丝通过有阻力、经调整仍无法顺利前进时建议退出穿刺针套管,重新穿刺。

桡动脉穿刺是 TRI 的关键步骤之一,虽然强调“The first hit is the best!”,但是穿刺成功率仍低于股动脉穿刺,这是导致 TRI 学习曲线较长的主要原因,我中心应用 PTCA 导丝置入桡动脉鞘管及导入造影导管提高了 TRI 成功率,具有重要的临床意义,据此开发相应的专利导丝可能有利于提高建立经桡动脉途径的成功率。但是该法操作相对复杂,初学者不易掌握,并且一定程度上增加了手术费用,所以并不能作为临床中的常规方法进行应用,仅可作为穿刺回血良好、无法置入直导丝时可供选择的方法之一,对女性、低体质量、动脉搏动弱及易痉挛或再次穿刺困难的患者更加适用。

4 利益冲突

所有作者声明本文不涉及任何利益冲突。

[参考文献]

- [1] Choussat R, Black A, Bossi I, Fajadet J, Marco J. Vascular complications and clinical outcome after coronary angioplasty with platelet II b/III a receptor blockade. Comparison of transradial vs transfemoral arterial access[J]. Eur Heart J, 2000, 21: 662-667.
- [2] Kiemeneij F, Laarman G J, Odekerken D, Slagboom T, van der Wieken R. A randomized comparison of percutaneous transluminal coronary angioplasty by the radial, brachial and femoral approaches: the access study [J]. J Am Coll Cardiol, 1997, 29: 1269-1275.
- [3] Rao S V, Ou F S, Wang T Y, Roe M T, Brindis R, Rumsfeld J S, et al. Trends in the prevalence and outcomes of radial and femoral approaches to percutaneous coronary intervention: a report from the National Cardiovascular Data Registry [J]. J ACC Cardiovasc Interv, 2008, 1: 379-386.
- [4] Yokoyama N, Takeshita S, Ochiai M, Koyama Y, Hoshino S, Isshiki T, et al. Anatomic variations of the radial artery in patients undergoing transradial coronary intervention [J]. Catheter Cardiovasc Interv, 2000, 49: 357-362.
- [5] Candemir B, Kumbasar D, Turhan S, Kilickap M, Ozdol C, Akyurek O, et al. Facilitation of radial artery cannulation by periradial subcutaneous administration of nitroglycerin [J]. J Vasc Interv Radiol, 2009, 20: 1151-1156.
- [6] 赵玉英, 汝磊生, 李俊峡, 王冬梅, 孙家安, 彭育红, 等. PTCA 导丝在经桡动脉冠状动脉造影桡动脉入径异常时的应用 [J]. 河北医药, 2011, 33: 2934-2935.
- [7] Jolly S S, Yusuf S, Cairns J, Niemelä K, Xavier D, Widimsky P, et al. RIVAL trial group. Radial versus femoral access for coronary angiography and intervention in patients with acute coronary syndromes (RIVAL): a randomised, parallel group, multicentre trial [J]. Lancet, 2011, 377: 1409-1420.

[本文编辑] 周燕娟, 孙岩